

”

RESEARCH and EVALUATIONS
in THE FIELD of
ENDODONTICS

EDITOR

PROF. DR. SADULLAH KAYA

İmtiyaz Sahibi • Yaşar Hız
Genel Yayın Yönetmeni • Eda Altunel
Yayına Hazırlayan • Gece Kitaplığı
Editor • Prof. Dr. Sadullah KAYA

Birinci Basım • October 2024 / ANKARA

ISBN • 978-625-388-013-2

© copyright

Bu kitabın yayın hakkı Gece Kitaplığı'na aittir.
Kaynak gösterilmeden alıntı yapılamaz, izin almadan
hiçbir yolla çoğaltılamaz.

Gece Kitaplığı

Adres: Kızılay Mah. Fevzi Çakmak 1. Sokak Ümit Apt
No: 22/A Çankaya/ANKARA Tel: 0312 384 80 40

www.gecekitapligi.com
gecekitapligi@gmail.com

Baskı & Cilt
Bizim Buro
Sertifika No: 42488

Research And Evaluations In The Field Of Endodontics

October 2024

Editor:
Prof. Dr. Sadullah KAYA

İÇİNDEKİLER

BÖLÜM 1

CURRENT IRRIGATION SOLUTIONS USED IN ENDODONTICS

Mustafa SAK, Nesrin BEYAZASLAN,

Neslihan Büşra KESKİN..... 1

BÖLÜM 2

VARIOUS ROOT CANAL OBTURATION METHODS FROM PAST TO PRESENT

Feyzanur ERGÜNER, Selen İNCE YUSUFOĞLU.....19

BÖLÜM 3

CURRENT IRRIGATION ACTIVATION METHODS

Büşra Nur ERGÜL, Beyza TURAN SAĞLAM,

Selen İNCE YUSUFOĞLU 37

BÖLÜM 4

THE EFFECT OF BARRIER MATERIALS USED IN REGENERATIVE ENDODONTIC TREATMENT ON DISCOLORATION AND TREATMENT METHODS

Şebnem DURUKAN, Özgün GÜLDEREN,

Esmâ SARIÇAM..... 57

BÖLÜM 5

EFFECT OF HEAD AND NECK RADIATION THERAPY ON ENDODONTIC TREATMENT

Özgün GÜLDEREN, Şebnem DURUKAN,

Esmâ SARIÇAM..... 79

BÖLÜM 6

VISUAL AIDS IN ENDODONTICS: THE ROLE OF MAGNIFICATION AND ILLUMINATION

İdil ÖZDEN.....117

CHAPTER 1

CURRENT IRRIGATION SOLUTIONS USED IN ENDODONTICS

Mustafa SAK¹

Nesrin BEYAZASLAN²

Neslihan Büşra KESKİN³

1 Department of Endodontics, Faculty of Dentistry, Ankara Yıldırım Beyazıt University, Ankara, Turkey, ORCID: 0009-0001-0020-3997

2 Department of Endodontics, Faculty of Dentistry, Ankara Yıldırım Beyazıt University, Ankara, Turkey, ORCID: 0009-0005-3399-7091

3 Department of Endodontics, Faculty of Dentistry, Ankara Yıldırım Beyazıt University, Ankara, Turkey, ORCID: 0000-0002-1053-7675

Endodontic treatment aims to remove all living and necrotic tissue, microorganisms and microbial by-products from the root canal system to allow the tooth to continue to function normally. Given the complex structure of root canals, mechanical shaping alone is not sufficient to achieve this goal. Studies have shown that the files used in mechanical shaping cannot reach a large part of the root canal system [1]. In addition to mechanical removal, chemical removal should be performed using irrigation solutions [2]. The use of chemical irrigation solutions together with mechanical preparation is called chemomechanical preparation [3]. Chemomechanical preparation aims to enlarge the root canals, to remove living and necrotic pulp residues, microorganisms, and exposed infected dentin chips [4].

Characteristics of an ideal irrigant [5], [6]:

- Bactericidal, antimicrobial, antifungal action,
- Lubrication during instrumentation,
- Dissolve inorganic and organic dentinal tissues,
- Does not irritate periapical tissues,

Long-lasting and sustained antibacterial activity after use,

- Activity in the presence of blood, serum and tissue protein products,
- Ability to completely remove the smear layer,
- Low surface tension,
- Disinfection of dentin and dentinal tubules,
- No inhibition of periapical tissue healing,
- No staining of dental tissues,
- Do not cause tooth tissue weakening,
- Do not induce a cell-mediated immune response,
- No antigenic, toxic, or carcinogenic effect on the cells of the periapical tissues of the tooth,
- No adverse effect on the physical properties of exposed dentin,
- No negative effect on the sealing ability of the root canal cushions,
- Easy to use and low cost,
- Long shelf life.

Current Irrigation Solutions

1. Sodium hypochlorite (NaOCl):

NaOCl is the most widely used rinsing solution due to its high antimicrobial activity against bacteria on biofilm, its success in dissolving biofilm and pulp tissue residues, its low cost, and its widespread availability[7].

NaOCl is sporicidal and virucidal with a broad antibacterial spectrum. It is more suitable necrotic tissue dissolving. The pH of NaOCl solutions is close to 11-12. This high pH causes disruptions in the cytoplasmic membrane of bacteria, cell metabolism, and lipid peroxidation. It can easily diffuse into dentin walls[8] and can be used as a lubricant during the use of rotary instruments[9].

Although a systematic review concluded that higher concentrations may offer an advantage [10], recent clinical trials have found no significant difference in the antimicrobial effect or healing of apical periodontitis between different NaOCl concentrations [10,11]. It has been reported in the literature that this solution destroys all microorganisms in the root canal in one minute or less[12].

Grossman and Meiman[13] reported that 5% NaOCl was dissolved organic tissue in times ranging from 20 minutes to 2 hours. Hand et al.[14] examined the effects of dilution of NaOCl solution on tissue dissolving power and reported that 2.5% NaOCl solution was approximately one-third as effective as 5.25% NaOCl, while 1% and 0.5% NaOCl solutions did not affect necrotic tissue.

Zehnder[15] and Christensen et al.[16] stated that 1% concentration of NaOCl is sufficient for antibacterial activity. Siqueira et al.[17] showed that 1% NaOCl was as effective as 5% NaOCl in the destruction of intra-canal microorganisms. However, Berber et al.[18] evaluated the effectiveness of 0.25%, 2.5%, and 5.25% NaOCl against *E. faecalis* and reported that the most effective solution was NaOCl with a concentration of 5.25%.

Siqueira et al.'s evaluation [19] of 4% NaOCl's anti-*Enterococcus Faecalis* (*E. Faecalis*) activity in vitro revealed that it was noticeably more successful at disinfecting the root canal than saline (the control group). Siqueira et al. used an agar diffusion test [20] to examine the antibacterial activity of several irrigants against four facultative and four black-pigmented anaerobic bacteria in a different investigation. According to their findings, 4% and 2.5% NaOCl had far stronger antibacterial action than the other studied drugs. Siqueira et al.'s study [21] revealed no variation in the 1%, 2.5%, and 5% NaOCl antibacterial efficacy.

Spratt et al.'s evaluation [22] assessed the effectiveness of phosphate buffered solution (PBS) as a control, 10% povidone iodine, 0.2% CHX, 2.25% NaOCl, 5 ppm colloidal silver, and 10% PBS against monoculture biofilms (*Intermedia*, *Peptostreptococcus mirus*, *Streptococcus intermedius*, *F. nucleatum*, *E. faecalis*). According to this study, NaOCl showed the most effective antimicrobial activity, followed by iodine solution. Clegg et al.[23] evaluated the effect of 3 different concentrations of NaOCl (6%, 3%, 1%), 2% CHX and MTAD (mixture of tetracycline, acid, detergent) on apical dentin biofilm in vitro. The results showed that 6% NaOCl was the only irrigant that removed the biofilm and eliminated microorganisms.

Gomes et al.[24], using blood diffusion test, found that the time required for 100% mortality in *E.faecalis* culture was 30 min in 0.5% NaOCl and 30 s in 5.25% NaOCl.

In another study investigating the effects of different solutions of NaOCl on *E.faecalis*, it was reported that 0.5% NaOCl eliminated *E.faecalis* in 30 min, 1% in 10 min, 2.5% in 5 min and 5.25% in 2 min [25].

Raphael et al.[26]found that 5.25% NaOCl at 21 and 37 °C did not make a difference in the antimicrobial activity of *E.faecalis*, *S. aureus*, and *P.aeruginosa* and even decreased it.

Karataş et al. compared postoperative pain scores with final irrigation with sodium hypochlorite at 3 different temperatures (NaOCl 2°C, NaOCl 25°C, and NaOCl 45°C). They conclude that equivalent antibacterial activity was obtained with final irrigation with NaOCl at varying temperatures. In terms of postoperative pain, they found that cold NaOCl (2°C) final irrigation was superior to NaOCl 45°C. (27).

2. Chlorhexidine

With broad-spectrum antibacterial activity against both Gram-positive and Gram-negative bacteria and yeasts, chlorhexidine (CHX) is a cationic bis-biguanide. CHX is both bacteriostatic and bactericidal, depending on the concentration. Elevated levels of CHX cause bacterial death and membrane damage to cells. Only bacteriostatic at low concentrations is chlorhexidine effective.

In a study comparing the antibacterial activity of different concentrations of CHX in vitro, it was found that the antibacterial activity of a 2% solution of CHX was more effective than a 0.12% solution. Therefore, the antibacterial activity of CHX has been shown to be concentration dependent [28].

Unlike NaOCl, CHX does not dissolve tissue. Therefore, NaOCl is still used as the primary irrigation solution in endodontics. In terms of root canal cleaning ability, 2 forms of CHX were compared in 2 different experiments using scanning electron microscopy (SEM). In an in vitro study, 2% CHX gel cleaned the canal much better than the canal treated with a combination of 2% CHX and 5.25% NaOCl.

This showed that the gel form was more effective in canal cleaning with mechanical effect. In another in vitro study, it was shown that 2% CHX was inferior to 2.5% NaOCl in canal cleaning [29]. However, in-vitro studies may not reflect the clinical reality compared to in-vivo studies. The antibacterial activity of CHX has been demonstrated in several in-vivo studies by reducing bacteria in the infected root canal. Ringel et al [30] reported that 2.5% NaOCl was more effective than 2% CHX in infected root canals by applying each solution for 30 min.

It has been demonstrated in recent research that CHX is a far less effective antibacterial than NaOCl [31, 32]. In contrast to what is commonly believed, at the same concentration, CHX is just as cytotoxic as or more so than NaOCl [33]. Furthermore, it forms a potentially hazardous orange-brown precipitate that may also result in discoloration when it combines with leftover NaOCl in the root canal [34]. In conclusion, the information that is now available opposes the use of CHX as a last irrigant[35].

3-Decalcifying Solutions

3.1. EDTA (Ethylenediaminetetraacetic acid)

Because it is a chelator and eliminates the mineralized portion of the smear layer, EDTA is a frequently used irrigation solution. The “sequestration” of di and tri cationic metal ions (like calcium and iron) in EDTA’s structure is what gives it its chelating properties.

EDTA alone is not effective in the removal of smear layer. It should be used in combination with NaOCl to remove the smear layer [36].

Typically, EDTA is used at a concentration of 17%. The solution works on the smear layer in significantly less time if it can cover the whole surface of the root canal walls. It restricts the actual decalcification process because it is a chelator. Because it opens calcified canals, EDTA plays a crucial role in the preparation of root canals. If given enough time, it can decalcify 50 µm and open highly calcified canals [6].

Grawehr (2003) conducted a study to investigate the interaction between NaOCl and EDTA [37]. This study showed that the calcium

complexing ability of EDTA did not change when mixed with NaOCl. Nevertheless, EDTA did reduce NaOCl's capacity to dissolve tissue, and the mixture contained no free chlorine. In a clinical setting, EDTA and NaOCl ought to be given apart.

When CHX and EDTA are used together, they form a white precipitate. Rasimick et al [38] reported CHX degradation in the precipitate. Dilute trifluoroacetic acid obtained from the precipitate was redissolved in a known amount. According to the results, CHX forms a salt with EDTA instead of undergoing a chemical reaction [39].

3.2. Citric Acid

Citric acid, like EDTA, is an effective agent for the removal of the smear layer in canal irrigation. Irrigation with sodium hypochlorite is recommended both before and after citric acid application for smear elimination. In a comparative study, 10% citric acid was reported to be more effective than 1% citric acid and more effective in terms of dentin demineralization than 17% EDTA [40]. However, Liolios et al. reported that 15% and 3% EDTA concentrations were more effective in dissolving the smear layer than 50% citric acid [41].

3.3. EDTA-T:

EDTA-T, which is a combination of EDTA and 0.2% lauryl sodium sulfate, a cationic detergent, increases the diffusion and efficacy of the detergent in the dentinal tubules (15).

3.4. HEBP (Etidronic Acid):

1-hydroxyethylen-1, 1-bisphosphonate is called etidronic acid. HEBP is a chelator that can be used as a compound with NaOCl apart from its effects providing proteolytic and antimicrobial properties [15]. It is thought to be the only chelator that can be used with NaOCl without affecting the antimicrobial properties of NaOCl. The use of the NaOCl+HEBP combination optimizes binding to resilon/epiphany root fillings [42].

3.5 Maleic Acid (MA)

The smear layer is successfully eliminated at concentrations of 5% and 7%. Particularly in the apical portion of the root canal system, Ballal et al. (2010) found that a 1-minute irrigation with 7% MA as the last irrigant eliminated the smear layer more successfully than a 1-minute irrigation

with 17% EDTA [43]. It has been shown that 7% MA causes higher surface roughening of the root canal walls than 17% EDTA. It was also discovered that maleic acid was less cytotoxic than EDTA [44].

4- Solutions Used in Combination

4.1. BioPure MTAD and Tetraclean

MTAD is a broad-spectrum antibiotic aqueous solution that was first introduced by Torabinejad and Johnson. It is capable of simultaneously disinfecting the root canal and removing the smear layer [45]. MTAD is a concoction of 0.5% polysorbate (Tween 80) detergent, 4.25% citric acid, and 3% doxycycline hyclate [88]. As directed by the manufacturer, MTAD should be used as a last rinse solution in clinical settings following the completion of traditional chemomechanical preparation [45, 46].

Tetraclean has demonstrated good antibacterial action against planktonic phase bacteria [47], but in a “ex vivo” model, it was found to have outstanding antimicrobial activity against *E faecalis* [48].

4.2. QMIX

Stojicic et al [49] evaluated the efficacy of Q-MIX on a biofilm of *E. faecalis* and mixed plaque bacteria and in the planktonic phase. They observed that application of Q-MIX and 1% NaOCI for 5 s killed all planktonic *E. faecalis* and plaque bacteria. They found that the effect of Q-MIX and 2% NaOCI on bacteria in the biofilm was more than 12 times greater than that of 1% NaOCI or 2% CHX.

4.3. Irritrol

Strong EDTA (17%) solutions are frequently used in conventional rinses to remove the smear layer, which significantly demineralizes the dentin. Irritrol’s proprietary blend of surfactants and chelators work in harmony to effectively remove the smear layer without excessive demineralisation. Because it does not include a considerable amount of EDTA, an irrigant that can chelate calcium ions and cause serious damage to the dentin surface, Irritrol is not an excessively “aggressive” irrigant [50]. In the study by Küçük et al, Irritrol demonstrated an ability to penetrate dentinal tubules similar to QMIX and CHX [51].

4.4. Smear Clear

A commercially available chelating agent called Smear Clear (SybronEndo, Orange, CA, USA) combines two additional proprietary surfactants with a 17% EDTA solution.

According to Ankur et al., Smear Clear and EDTA performed comparably when it came to eliminating the smear layer from the middle third of the root canal. But in the apical third, Smear Clear considerably outperformed 17% EDTA solution in terms of smear layer removal [52].

In a study by Luciano et al. measuring the dentinal tubule penetration depth of 17% EDTA, Smear Clear and BioAKT Endo, viscosity and surface tension tests showed that BioAKT Endo had the lowest values than EDTA and Smear Clear [53].

4.5. Triton

Triton demonstrated significantly higher bacterial killing and smear layer removal for both *E. faecalis* and multi-species biofilms in dentinal canals compared to NaOCl or NaOCl + EDTA, according to an evaluation by Xuyan et al. of the drug's effectiveness in eliminating single and multi-species oral biofilms and smear layers in dentinal canals [54].

Comparing 6% NaOCl (5 minutes) and 6% NaOCl + 17% EDTA (5 + 1 minutes) to Triton used for 3 minutes and then another 3 minutes treatment, the results indicated a much higher bacterial death of biofilms [54].

5- Herbal Medicines Used as Irrigation Solution:

Despite the good tissue dissolving ability and strong antimicrobial activity of chemical agents, problems and safety concerns due to their unpleasant taste and odor, tissue toxicity, weakening of tooth structures by reducing dentin structural integrity, etc. have increased the interest in medicinal plants. Since ancient times, plants have been used for many medicinal purposes (55).

Herbal medicine is defined by the World Health Organization (WHO) as any material or preparation generated from plants that contains raw or processed parts of one or more plants that have therapeutic effect [56]. Currently, herbal products are widely used in dentistry and medicine because of their strong antibacterial, biocompatible, anti-inflammatory, and antioxidant qualities [57]. Herbal preparations made from a variety of plant materials, including roots, seeds, leaves, stems, and flowers, have been utilized as endodontic irrigants, analgesics, sedatives, anti-inflammatory agents, and antibiotics in dentistry [58].

5.1. *Morinda Citrifolia* (Indian Mulberry, Noni, Nono, Ba Ji Tian, Cheese Fruit)

Commercially known as Noni, *Morinda citrifolia* (MCJ) is one of the traditional medicinal plants utilized for over 2000 years in Polynesia (59). Numerous medicinal benefits of noni juice have been discovered. The antimicrobial, antiviral, analgesic, anticancer, antihelminthic, hypotensive, and immune-enhancing properties are among them [60].

It has been demonstrated that the main components of these plants are vitamin C, scopoletin, potassium, terpenoids, alkaloids, alizarin, anthraquinones, vitamin A, carotene, linoleic acid, amino acids, caproic acid, caprylic acid, rutin, and maybe proxeronin. The following bacteria are effectively combated by these substances: *Salmonella*, *Shigella*, *Bacillus subtilis*, *Pseudomonas aeruginosa*, *Escherichia coli*, *Pseudomonas aureus*, and *Bacillus subtilis* [61]. For root canal irrigation, MCJ is the first herbal substitute for NaOCl [62, 63].

According to Murray et al., 14% *M. citrifolia* in combination with EDTA produced more effective smear removal than 5.25% NaOCl. If MCJ is to be used as an endodontic irrigation solution, EDTA irrigation followed by a final MCJ irrigation is recommended [62].

5.2. Propolis (Bee Glue)

Propolis contains flavonoids, aromatics, and phenolics, which are its pharmacologically active ingredients. Additional components consist of 50–70% resin and balm, essential oil, 30–50% sand wax, and 5–10% pollen. There are other minerals, vitamins A, E, and B complex, and amino acids. Additionally present is a highly active molecule called bioflavonoid (vitamin P) [64]. Propolis possesses a variety of biological actions, including as cytotoxic, anesthetic, antibacterial, and anti-inflammatory effects. Flavonoids and cinnamic acid derivatives have been considered as the primary biologically active components [65]. The antimicrobial property of propolis is mainly against gram-positive bacteria such as *Enterococcus spp*, *Mycobacteria spp*, *S. Aureus* [66]. In dentistry, propolis is used in the treatment of aphthous ulcers, candida albicans, gingivitis, acute necrotising ulcerative gingivitis, and periodontitis [67]. Since propolis has good antimicrobial and anti-inflammatory properties, it is thought to be used as an intra-canal irrigation and medicament [67,68]. In a study by Al-Qathami and Al-Madi, the antimicrobial activity of propolis, NaOCl and saline as irrigation agents was evaluated and it

was shown that propolis had equal antimicrobial activity to NaOCl [69]. In a study by Kandaswamy et al, propolis was found to have better antimicrobial activity against *E. faecalis* than calcium hydroxide, but less than CHX. This result suggests that propolis can be used as an alternative intra-canal medication [70].

A 2014 study showed that propolis was as effective as NaOCl against *E. faecalis* biofilm and more effective than triphala, neem, and green tea [69]. In a study by Madhubala et al. ethanolic extract of propolis was found to be more effective than triple antibiotic paste against *E. faecalis* at the end of 2 days [70]. In an in vivo study on samples from 60 children aged 6-12 years with acute apical abscess, the effects of propolis, calcium hydroxide, and CHX on endodontic aerobic and anaerobic bacteria were evaluated and propolis was shown to be effective in reducing aerobic bacteria. In this study, it was also found that its effect was higher than calcium hydroxide [73]. There is also a study that propolis can be used effectively in combination with calcium hydroxide for the elimination of endodontic pathogens, especially against *E. faecalis* (17). Propolis also promotes the formation of hard tissue bridges. This property has been attributed to its ability to stimulate various enzyme systems, cell metabolism, circulation and collagen formation [74]. Sabir et al (2005) reported in a mouse study that direct pulp capping with propolis can delay pulp inflammation and stimulate regenerative dentin formation [72]. Ethanol extract of propolis promotes bone regeneration and induces hard tissue bridging in pulpotomies or pulp capping cases [73]. There are also studies suggesting that propolis may be used for dentin sensitivity as it can occlude dentin tubules [66].

Recommended Irrigation protocol

NaOCl is still the recommended primary irrigation solution to be used during the chemomechanical preparation process because of its effectiveness in eliminating organic components from the smear layer, dissolving pulp tissue residues, disrupting the biofilm structure, and killing microorganisms. It also has lubricating qualities. After instrumentation, the root canal should be washed with a chelator, such as EDTA, to partially rupture the biofilm matrix and remove accumulated hard tissue debris and inorganic components of the smear layer.

It is not appropriate to think of this phase as the last rinse, though. In order to operate on the remaining biofilm and further penetrate the dentinal

tubules that have been liberated from the smear layer, NaOCl needs to be reintroduced into the root canal system. The use of CHX or any other irrigant in place of NaOCl for the final rinse is not supported by the available data. HEDP is a mild chelator combination that, when paired with NaOCl, can further simplify this irrigation protocol.

CONCLUSION

Root canal shape and the total elimination of bacteria and their by-products from root canals are challenging due to the intricate architecture of teeth and root canals. Moreover, antimicrobial irrigation solutions and drugs are less efficient against all microorganisms prevalent in endodontic infections due to the complicated chemical environment of the root canal [72].

No one irrigant possesses all the necessary qualities of an irrigation solution, even if sodium hypochlorite is the most significant irrigation solution [73]. In order to achieve optimal root canal sterilization and disinfection, it is recommended to combine several irrigation solutions.

Future multidisciplinary research integrating concepts from fundamental sciences like fluid dynamics, microbiology, and chemistry could eventually result in more potent antimicrobials and improved cleaning of the intricate root canal system's difficult-to-reach regions.

KAYNAKÇA

1. Peters, O. A. (2004). Current challenges and concepts in the preparation of root canal systems: a review. *Journal of endodontics*, 30(8), 559-567.
2. Topbas, C., & Adiguzel, O. (2017). Endodontic irrigation solutions: A review: Endodontic irrigation solutions. *International Dental Research*, 7(3), 54-61.
3. Harrison, J. W. (1984). Irrigation of the root canal system. *Dental Clinics of North America*, 28(4), 797-808.
4. Tirali, R. E. (2009). Endodontide Kullanılan İrrigasyon Solusyonları. *ADO Klinik Bilimler Dergisi*, 3(2), 368-373.
5. Agrawal Vineet, S., Rajesh, M., Sonali, K., & Mukesh, P. (2014). A contemporary overview of endodontic irrigants—A review. *J Dent App*, 1(6), 105-15.
6. Basrani, B., & Haapasalo, M. (2012). Update on endodontic irrigating solutions. *Endodontic topics*, 27(1), 74-102.
7. Dutner, J., Mines, P., & Anderson, A. (2012). Irrigation trends among American Association of Endodontists members: a web-based survey. *Journal of endodontics*, 38(1), 37-40.
8. Fraiss, S., Ng, Y. L., & Gulabivala, K. (2001). Some factors affecting the concentration of available chlorine in commercial sources of sodium hypochlorite. *International endodontic journal*, 34(3), 206-215.
9. Boessler, C., Peters, O. A., & Zehnder, M. (2007). Impact of lubricant parameters on rotary instrument torque and force. *Journal of endodontics*, 33(3), 280-283.
10. Fedorowicz, Z., Nasser, M., Sequeira-Byron, P., de Souza, R. F., Carter, B., & Heft, M. (2012). Irrigants for non-surgical root canal treatment in mature permanent teeth. *Cochrane Database of Systematic Reviews*, (9).
11. Verma, N., Sangwan, P., Tewari, S., & Duhan, J. (2019). Effect of different concentrations of sodium hypochlorite on outcome of primary root canal treatment: a randomized controlled trial. *Journal of endodontics*, 45(4), 357-363.
12. Mohammadi, Z. (2008). Sodium hypochlorite in endodontics: an update review. *International dental journal*, 58(6), 329-341.
13. Grossman, L. I., & Meiman, B. W. (1941). Solution of pulp tissue by chemical agents. *The Journal of the American Dental Association*, 28(2), 223-225.
14. Hand, R. E., Smith, M. L., & Harrison, J. W. (1978). Analysis of the effect of dilution on the necrotic tissue dissolution property of sodium hypochlorite. *Journal of endodontics*, 4(2), 60-64.
15. Zehnder, M. (2006). Root canal irrigants. *Journal of endodontics*, 32(5), 389-398.
16. Christensen, C. E., McNeal, S. F., & Eleazer, P. (2008). Effect of lowering the pH of sodium hypochlorite on dissolving tissue in vitro. *Journal of Endodontics*, 34(4), 449-452.

17. Siqueira Jr, J. F., Rôças, I. N., Favieri, A., & Lima, K. C. (2000). Chemomechanical reduction of the bacterial population in the root canal after instrumentation and irrigation with 1%, 2.5%, and 5.25% sodium hypochlorite. *Journal of endodontics*, 26(6), 331-334.
18. Siqueira Jr, J. F., Machado, A. G., Silveira, R. M., Lopes, H. P., & De Uzeda, M. (1997). Evaluation of the effectiveness of sodium hypochlorite used with three irrigation methods in the elimination of *Enterococcus faecalis* from the root canal, in vitro. *International endodontic journal*, 30(4), 279-282.
19. Siqueira Jr, J. F., Batista, M. M., Fraga, R. C., & de Uzeda, M. (1998). Antibacterial effects of endodontic irrigants on black-pigmented gram-negative anaerobes and facultative bacteria. *Journal of endodontics*, 24(6), 414-416.
20. Siqueira Jr, J. F., Rôças, I. N., Favieri, A., & Lima, K. C. (2000). Chemomechanical reduction of the bacterial population in the root canal after instrumentation and irrigation with 1%, 2.5%, and 5.25% sodium hypochlorite. *Journal of endodontics*, 26(6), 331-334.
21. Spratt, D. A., Pratten, J., Wilson, M., & Gulabivala, K. (2001). An in vitro evaluation of the antimicrobial efficacy of irrigants on biofilms of root canal isolates. *International endodontic journal*, 34(4), 300-307.
22. Clegg, M. S., Vertucci, F. J., Walker, C., Belanger, M., & Britto, L. R. (2006). The effect of exposure to irrigant solutions on apical dentin biofilms in vitro. *Journal of endodontics*, 32(5), 434-437.
23. Gomes, B. P. F. A., Ferraz, C. C. R., ME, V., Berber, V. B., Teixeira, F. B., & Souza-Filho, F. J. (2001). In vitro antimicrobial activity of several concentrations of sodium hypochlorite and chlorhexidine gluconate in the elimination of *Enterococcus faecalis*. *International endodontic journal*, 34(6), 424-428.
24. Raphael, D., Wong, T. A., Moodnik, R., & Borden, B. G. (1981). The effect of temperature on the bactericidal efficiency of sodium hypochlorite. *Journal of Endodontics*, 7(7), 330-334.
25. Karataş, E., Ayaz, N., UlukÖylü, E., Baltacı, M. Ö., & Adigüzel, A. (2021). Effect of final irrigation with sodium hypochlorite at different temperatures on postoperative pain level and antibacterial activity: a randomized controlled clinical study. *Journal of Applied Oral Science*, 29, e20200502.
26. Basrani, B., Tjäderhane, L., Santos, J. M., Pascon, E., Grad, H., Lawrence, H. P., & Friedman, S. (2003). Efficacy of chlorhexidine-and calcium hydroxide-containing medicaments against *Enterococcus faecalis* in vitro. *Oral surgery, oral medicine, oral Pathology, oral Radiology, and endodontology*, 96(5), 618-624.
27. Yamashita, J. C., Tanomaru Filho, M., Leonardo, M. R., Rossi, M. A., & Silva, L. A. B. D. (2003). Scanning electron microscopic study of the cleaning ability of chlorhexidine as a root-canal irrigant. *International endodontic journal*, 36(6), 391-394.

28. Ringel, A. M., Patterson, S. S., Newton, C. W., Miller, C. H., & Mulhern, J. M. (1982). In vivo evaluation of chlorhexidine gluconate solution and sodium hypochlorite solution as root canal irrigants. *Journal of Endodontics*, 8(5), 200-204.
29. Busanello, F. H., Petridis, X., So, M. V., Dijkstra, R. J., Sharma, P. K., & van der Sluis, L. W. (2019). Chemical biofilm removal capacity of endodontic irrigants as a function of biofilm structure: optical coherence tomography, confocal microscopy and viscoelasticity determination as integrated assessment tools. *International Endodontic Journal*, 52(4), 461-474.
30. Ruiz-Linares, M., Aguado-Pérez, B., Baca, P., Arias-Moliz, M. T., & Ferrer-Luque, C. M. (2017). Efficacy of antimicrobial solutions against polymicrobial root canal biofilm. *International endodontic journal*, 50(1), 77-83.
31. Boutsoukis, C., & Arias-Moliz, M. T. (2022). Present status and future directions—irrigants and irrigation methods. *International Endodontic Journal*, 55, 588-612.
32. Scott II, M. B., Zilinski, G. S., Kirkpatrick, T. C., Himel, V. T., Sabey, K. A., & Lallier, T. E. (2018). The effects of irrigants on the survival of human stem cells of the apical papilla, including endocyn. *Journal of Endodontics*, 44(2), 263-268.
33. Scott II, M. B., Zilinski, G. S., Kirkpatrick, T. C., Himel, V. T., Sabey, K. A., & Lallier, T. E. (2018). The effects of irrigants on the survival of human stem cells of the apical papilla, including endocyn. *Journal of Endodontics*, 44(2), 263-268.
34. Goldman, M., Kronman, J. H., Goldman, L. B., Clausen, H., & Grady, J. (1976). New method of irrigation during endodontic treatment. *Journal of endodontics*, 2(9), 257-260.
35. Grawehr, M., Sener, B., Waltimo, T., & Zehnder, M. (2003). Interactions of ethylenediamine tetraacetic acid with sodium hypochlorite in aqueous solutions. *International endodontic journal*, 36(6), 411-415.
36. Rasimick, B. J., Nekich, M., Hladek, M. M., Musikant, B. L., & Deutsch, A. S. (2008). Interaction between chlorhexidine digluconate and EDTA. *Journal of endodontics*, 34(12), 1521-1523.
37. Önay, E. O., Kurt, E., Kızıllırmak, İ., Nuyan, D., Güran, Ç., & Erdoğan, T. (2013). Kök Kanal İrrigasyonunda Geleneksel ve Güncel Yaklaşımlar. *ADO Klinik Bilimler Dergisi*, 7(2), 1459-1468.
38. Liolios, E., Economides, N., Parisis-Messimeris, S., & Boutsoukis, A. (1997). The effectiveness of three irrigating solutions on root canal cleaning after hand and mechanical preparation. *International Endodontic Journal*, 30(1), 51-57.
39. De-Deus, G., Namen, F., Galan Jr, J., & Zehnder, M. (2008). Soft chelating irrigation protocol optimizes bonding quality of Resilon/Epiphany root fillings. *Journal of endodontics*, 34(6), 703-705.

40. Ballal, N. V., Kandian, S., Mala, K., Bhat, K. S., & Acharya, S. (2009). Comparison of the efficacy of maleic acid and ethylenediaminetetraacetic acid in smear layer removal from instrumented human root canal: a scanning electron microscopic study. *Journal of endodontics*, 35(11), 1573-1576.
41. Ballal, N. V., Kundabala, M., Bhat, S., Rao, N., & Rao, B. S. (2009). A comparative in vitro evaluation of cytotoxic effects of EDTA and maleic acid: root canal irrigants. *Oral Surgery, Oral Medicine, Oral Pathology, Oral Radiology, and Endodontology*, 108(4), 633-638.
42. Torabinejad, M., Shabahang, S., Aprecio, R. M., & Kettering, J. D. (2003). The antimicrobial effect of MTAD: an in vitro investigation. *Journal of endodontics*, 29(6), 400-403.
43. Baumgartner, J. C., Johal, S., & Marshall, J. G. (2007). Comparison of the antimicrobial efficacy of 1.3% NaOCl/BioPure MTAD to 5.25% NaOCl/15% EDTA for root canal irrigation. *Journal of endodontics*, 33(1), 48-51.
44. Giardino, L., Ambu, E., Savoldi, E., Rimondini, R., Cassanelli, C., & Debbia, E. A. (2007). Comparative evaluation of antimicrobial efficacy of sodium hypochlorite, MTAD, and Tetraclean against *Enterococcus faecalis* biofilm. *Journal of endodontics*, 33(7), 852-855.
45. Rimoldi, C., Ardizzoni, A., Neglia, R. G., Blasi, E., Generali, L., & Ambu, E. (2006). In vitro and ex vivo studies on the antibacterial efficacy of sodium hypochlorite and two new generation endodontic irrigants, Tetraclean® and MTAD, in comparison with sodium hypochlorite. *Giornale Italiano di Endodonzia*, 20, 37-38.
46. Stojcic, S., Shen, Y., Qian, W., Johnson, B., & Haapasalo, M. (2012). Antibacterial and smear layer removal ability of a novel irrigant, QMiX. *International endodontic journal*, 45(4), 363-371.
47. <https://www.edsdental.com/irritrol/>
48. Kūçük, M., & Kermeoğlu, F. (2019). Efficacy of different irrigation methods on dentinal tubule penetration of Chlorhexidine, QMix and Irritrol: A confocal laser scanning microscopy study. *Australian Endodontic Journal*, 45(2), 202-208.
49. Dua, A., Dua, D., & Uppin, V. M. (2015). Evaluation of the effect of duration of application of smear clear in removing intracanal smear layer: SEM study. *Saudi Endodontic Journal*, 5(1), 26-32.
50. Giardino, L., Pedullà, E., Cavani, F., Bisciotti, F., Giannetti, L., Checchi, V., ... & Generali, L. (2021). Comparative evaluation of the penetration depth into dentinal tubules of three endodontic irrigants. *Materials*, 14(19), 5853.
51. Tewari, R. K., Kapoor, B., Mishra, S. K., & Kumar, A. (2016). Role of herbs in endodontics. *Journal of Oral Research and Review*, 8(2), 95-99.
52. Pujar, M., & Makandar, S. D. (2011). Herbal usage in endodontics-A review. *International journal of contemporary dentistry*, 2(1).

53. Parle, M., & Bansal, N. (2006). Herbal medicines: are they safe?.
54. Manjunatha, M., & Kini, A. (2016). Botanicals in endodontics: A review. *Journal of Advanced Clinical and Research Insights*, 3(5), 173-176.
55. Zhu, Y. P., & Woerdenbag, H. J. (1995). Traditional Chinese herbal medicine. *Pharmacy World and Science*, 17, 103-112.
56. Sinha, D. J., & Sinha, A. A. (2014). Natural medicaments in dentistry. *AYU (An international quarterly journal of research in Ayurveda)*, 35(2), 113-118.
57. Yoshida, T., Shibata, T., Shinohara, T., Gomyo, S., & Sekine, I. (1995). Clinical evaluation of the efficacy of EDTA solution as an endodontic irrigant. *Journal of endodontics*, 21(12), 592-593.
58. Saghiri, M. A., García-Godoy, F., Asgar, K., & Lotfi, M. (2013). The effect of *Morinda Citrifolia* juice as an endodontic irrigant on smear layer and microhardness of root canal dentin. *Oral Science International*, 10(2), 53-57.
59. Kayaoglu, G., Ömürlü, H., Akca, G., Gürel, M., Gençay, Ö., Sorkun, K., & Salih, B. (2011). Antibacterial activity of Propolis versus conventional endodontic disinfectants against *Enterococcus faecalis* in infected dentinal tubules. *Journal of endodontics*, 37(3), 376-381.
60. Barreto, S. L. D. T., Pereira, C. A., Umigi, R. T., Rocha, T. C. D., Araujo, M. S. D., Silva, C. S., & Torres Filho, R. D. A. (2007). Determinação da exigência nutricional de cálcio de codornas japonesas na fase inicial do ciclo de produção. *Revista Brasileira de Zootecnia*, 36, 68-78.
61. Canavar, T., Eren, İ., & Bayram, M. (2020). Endodontide İrrigasyon Solüsyonu Olarak Kullanılan Bitkisel Alternatifler. *Dental and Medical Journal-Review*, 2(3), 156-173.
62. Banskota, A. H., Tezuka, Y., & Kadota, S. (2001). Recent progress in pharmacological research of propolis. *Phytotherapy research*, 15(7), 561-571.
63. Oncag, O., Cogulu, D., Uzel, A., & Sorkun, K. (2006). Efficacy of propolis as an intracanal medicament against *Enterococcus faecalis*. *General dentistry*, 54(5), 319-322.
64. Hind, A. Q., & Ebtissam, A. M. (2004). < A> comparison of sodium hypochlorite, propolis and saline as a root-canal irrigant: SEM study.
65. Kandaswamy, D., Venkateshbabu, N., Gogulnath, D., & Kindo, A. J. (2010). Dentinal tubule disinfection with 2% chlorhexidine gel, propolis, morinda citrifolia juice, 2% povidone iodine, and calcium hydroxide. *International endodontic journal*, 43(5), 419-423.
66. Garg, P., Tyagi, S. P., Sinha, D. J., Singh, U. P., Malik, V., & Maccune, E. R. (2014). Comparison of antimicrobial efficacy of propolis, *Morinda citrifolia*, *Azadirachta indica*, triphala, green tea polyphenols and 5.25% sodium hypochlorite against *Enterococcus fecalis* biofilm. *Saudi endodontic journal*, 4(3), 122-127.

67. Madhubala, M. M., Srinivasan, N., & Ahamed, S. (2011). Comparative evaluation of propolis and triantibiotic mixture as an intracanal medicament against *Enterococcus faecalis*. *Journal of endodontics*, 37(9), 1287-1289.
68. Jolly, M., Singh, N., Rathore, M., Tandon, S., & Banerjee, M. (2013). Propolis and commonly used intracanal irrigants.: Comparative evaluation of antimicrobial potential. *Journal of Clinical Pediatric Dentistry*, 37(3), 243-249.
69. Sabir, A., Tabbu, C. R., Agustiono, P., & Sosroseno, W. (2005). Histological analysis of rat dental pulp tissue capped with propolis. *Journal of oral science*, 47(3), 135-138.
70. Kusum, B., Rakesh, K., & Richa, K. (2015). Clinical and radiographical evaluation of mineral trioxide aggregate, biodentine and propolis as pulpotomy medicaments in primary teeth. *Restorative dentistry & endodontics*, 40(4), 276-285.
71. Jahromi, M. Z., Toubayani, H., & Rezaei, M. (2012). Propolis: a new alternative for root canal disinfection. *Iranian endodontic journal*, 7(3), 127.
72. Iqbal, A. (2012). Antimicrobial irrigants in the endodontic therapy. *International journal of health sciences*, 6(2), 186.
73. Haapasalo, M., Shen, Y., Qian, W., & Gao, Y. (2010). Irrigation in endodontics. *Dental Clinics*, 54(2), 291-312.

CHAPTER 2

VARIOUS ROOT CANAL OBTURATION METHODS FROM PAST TO PRESENT

Feyzanur ERGÜNER¹

Selen İNCE YUSUFOĞLU²

1 Department of Endodontics, Faculty of Dentistry, Ankara Yıldırım Beyazıt University, Ankara, Turkey ORCID: 0009-0007-6224-259X

2 Department of Endodontics, Faculty of Dentistry, Ankara Yıldırım Beyazıt University, Ankara, Turkey ORCID: 0000-0002-7826-6023

An essential component influencing the extended period achievement of an endodontic treatment is that the root canal system is completely obturated after biomechanical preparation to be able to avoid oral pathogens from re-colonizing the root and periapical tissues and causing infection (Guimaraes vd., 2014). To date, there is little proof to back up the superiority of one method of obturation over another based on outcome evaluation studies. According to research conducted in Toronto, warm vertical compaction might be preferable to lateral compaction (Chevigny vd., 2008). Nevertheless, there is no definitive evidence.

Many obturation techniques have been created for root canal treatment and each technique has its own advantages and disadvantages. When we need to choose between many techniques with the aim of clinical success, the most practical and operator-friendly technique that can achieve a predictable result should be preferred, according to the anatomy of the root canal and the degree of difficulty of the case.

1. Cold Obturation Methods

1.1. Single Cone Technique

With the widespread utilize of rotary nickel titanium files in shaping root canals, angled guttapercha cones compatible with the increasing taper and diameter of the rotary file used in the canal have been introduced to the market (Chandler vd., 2005). In the single cone technique, a single gutta-percha cone that is exactly compatible with the taper angle of the last file used in the root canal is placed in the canal at the working length with a suitable sealer and the filling process is performed by removing the coronal excess with the help of a heated instrument (Kaplan vd., 2019). According to the manufacturer's claim, this technique provides a higher gutta-percha volume in the canal and a 3-dimensional obturation in a shorter time (Schäfer vd., 2012). The single cone technique does not require the addition of an auxiliary cone or the application of lateral condensation along with the main cone (Pereira vd., 2012). In cases where the condensation process is not applied and there are possible anatomical variations in the root canal (oval-shaped canals, internal resorption, etc.), these areas will be filled with a higher volume of paste, making this technique less effective in sealing the root canal (Pereira, 2012). Since the intensify in the content of sealer in the root canal, the shrinkage of the sealer as it hardens, its dissolution with tissue fluids, or possible cavities that may occur in the sealer, compromise the root canal treatment's long-term effectiveness (Monticelli vd., 2007).

1.2. Cold Lateral Condensation Method

One of the most popular endodontic techniques is the cold lateral compaction method using gutta-percha (Cailleateau & Mullaney, 1997). After the biomechanical root canal preparation is completed, a standard master cone compatible with the diameter of the final file used in the canal is placed in the canal with the addition of root canal sealer. If the selected master cone is compatible with the apical ending, there should be a sense of compression or —tug-back resistance when withdrawn. After the main cone is placed in the canal, it is compressed laterally within the canal with the help of a spreader and auxiliary cones are added to the created spaces. The auxiliary cone addition is continued till the spreader does not advance more than 2-3 mm in the root canal. Finally, to complete the filling process, excess gutta-percha accumulated in the coronal is removed with the help of a heated tool or gutta-cutters (Zmener & Banages, 1999).

It is a successful technique that is frequently preferred because it is simple and easy to apply, does not require special and expensive instruments, and is low cost (Frantzeska vd., 2017). The controllability of the apical fit reduces the danger of apical extrusion of the root canal filling material compared to other techniques (Alaçam, 2012). However, the capacity for homogeneously obturate the cleaned and shaped root canal space to give it its original form is questionable (López & Estrada, 2018). Its use in filling root canals with anatomical irregularities such as excessive curvature, amorphous shape or internal resorption poses a problem in terms of creating a hermetic obturation (Alaçam, 2012). In addition, the risk of creating a void between gutta-percha cones and root canal walls and the resulting increase in the breadth of the sealer used, and the bias of vertical root fracture due to excessive pressure applied with the spreader during condensation can be listed among the disadvantages (Pişkin et al., 2008).

1.3. Guttaflow

Gutta flow contains gutta-percha powders and is in injectable form with a fluid consistency. It is known as the cold fluid gutta-percha technique. It is biocompatible. It adapts to canal irregularities, the setting time changes with sodium hypochlorite. It shows 2% expansion in the root canal (Punia et al, 2011). However, the sealing was found to be lower than many sealers. (Elayouti et al 2005).

2. Warm Obturation Techniques

2.1. Warm Vertical Condensation Technique (Schilder tekniği)

The warm vertical condensation method was developed by Schilder in 1967 as a technique that can fill the root canal homogeneously in 3-D, with maximum gutta-percha and minimum root canal sealer, and is dense, dimensionally stable (Schilder, 1967). Briefly, the technique is based on the principle of applying vertical pressure to the heated gutta-percha, thus allowing the mellowed gutta-percha to fill the total lumen and irregularities of the canal (Tomson et al., 2014).

After the root canal sealer is placed in the canal, a non-standard master cone compatible with the apical tug-back that resists displacement is placed into the canal 0.5-2 mm shorter than the working length, and the coronal part of the gutta-percha is removed with a heated instrument. The heated gutta-percha is compressed apically with a plugger until the apical part is obturated. To obturate the coronal canal space, small 3-4 mm gutta-percha pieces are placed into the canal and heat is applied. Then, the gutta-percha pieces softened by heat are compressed vertically with the help of a plugger or spreader compatible with the canal and the obturation is completed (Tomson et al, 2014). The Touch 'n Heat unit (CourtesySybronEndo, Orange, CA) and System B (Kerr Dental, SybronEndo, Orange, CA) are superior temperature control options when compared to using a flame-heated instrument to apply heat (Tomson et al, 2014). The flame hot emitter has no temperature control and the Touch 'n Heat checks only deliver heat to the tip and do not provide feedback from the tip as per clinical conditions. Because System B is equipped with an inbuilt computer, it is able to monitor tip temperature and respond to feedback according to clinical conditions, ensuring the tip remains at the set temperature (Tomson et al, 2014).

Warm gutta-percha obturation techniques offer adequate filling of lateral canals and intracanal irregularities in the anatomic root canal complex. (Keleş, 2014 ; Suguro, 2018). In a study based on this information, it was stated that the quantity of lateral canals obturated with hot vertical condensation techniques was about twice that obtained with the lateral condensation technique (Brothman, 1981). Suguro, 2018

The drawbacks of the technique can be enumerated in the following order; the force applied with the plugger used to compress the heated gutta-percha vertically may create a risk of vertical root fracture, and the use of rigid pluggers in inclined root canal systems is quite difficult because they can not penetrate deep enough to provide ideal obturation. To achieve this, the canals need to be widened further, which leads to thinning of the

root canal walls and thus waning the root and making it susceptible to root fractures (Blum et al., 1997). Compared to lateral condensation, length control is poorer, thus increasing the potential for extrusion of gutta-percha and root canal sealer into periradicular tissues (Kytridou et al., 1999). These days, it is acknowledged that the temperature created on the root surface should be kept around 10 °C to avoid bone damage. Dentin provides a comparatively favorable seal, but the possibility of a temperature increase on the external root surfaces resulting in an there have been reports of alveolar bone response following the application of certain popular heat-assisted obturation procedures (Cen et al., 2018).

2.2. Warm Lateral Condensation Technique

The warm lateral condensation technique was developed by combining the dimensional control of cold lateral condensation with the irregularity filling properties provided by warm guttapercha techniques. Endotec II, EndoTwin, Thermopact devices have been developed for this process and System B can also be used (Clinton et al, 2001). Dr. Harvard Martin developed the

—Endotect III device, which is a battery-operated, temperature-controlled spreader/plugger used to provide lateral and vertical condensation (Jain et al., 2016). The researchers investigated that warm lateral condensation with Endotec II enhanced the gutta percha's mass weight by 14.63% in comparison to traditional cold lateral condensation (Liewehr et al., 1993). It is also reported that EndotectII is compatible with all curved canal preparation methods and offers a three-dimensional filling with its calibrated temperature, reduces the potential for cracks and fractures by producing less stress during lateral compaction (Martin et al., 1990), and the use of the device has no harmful effect on the integrity of periodontal tissues (Castelli, 1991).

The —EndoTwinn (EndoTwinn B.V., Amsterdam, The Netherlands) device, which was developed with the idea of using heat and vibration together, is also used with the warm lateral condensation technique (Pagavino et al., 2006). EndoTwinn has the ability to vibrate as well as heat, and thus it is possible to obtain a more homogeneous filling in the canal defects by increasing the flow of thermoplasticized gutta-percha and reducing the number and size of voids (Kulild et al., 2007). The vibration frequency of EndoTwinn is lower than the ultrasonic frequency and is around 100 Hz (Kaplan et al., 2019). Another device introduced in 2007 as a variation of the EndoTwinn is the —DownpakI, a cordless and multipurpose endodontic heating and trembling spreader. It is currently used under the name

—Rootbuddy[®]. It is applicable to both lateral and vertical condensation (Berman ve Hargreaves, 2021).

2.3. Thermohydraulic Compaction (The)

The root canal filling technique developed by Dr. Buchanan, using System B, Obtura II and Dovgan heat source, was modified and the hydrostatic pressure created during the down packing process was increased. It is claimed that by increasing the thermal hydraulic pressure in this technique, the lateral canal can be obturated more successfully (Nahmias et al., 2001).

3. Termomechanic Compaction

3.1. McSpadden Technique

Mcspadden introduces the McspaddenCompactor, which is similar to the Hedström file but has reverse flutes (Leonardo et al., 2004). When the micromotor is activated, the instrument creates friction, softens the gutta-percha and advances it apically. Similar rotary compactors have been developed in terms of design. The device is made of nickel titanium to increase flexibility (Berman ve Hargreaves, 2021). Advantages include simplicity of the technique, effectiveness and duration of obturating root canal irregularities (EM, 1989). Disadvantages include possible material spillage, tool breakage, the formation of grooves in the canal wall, the incapacity of method to be used in curved canals and potential overheating (EM, 1990).

3.2. MicroSeal technique

It is a technique applied by using the Microflow main cone, which has the feature of flowing under pressure, the Microflow cartridge, which becomes fluid with 15 seconds of heating in the heater device, and the Microsealcondenser operating at 5000-7000 rpm. After the main cone compatible with the final apical diameter is placed in the canal with a sealer, a space is created next to the main cone with the canal probe and a microseal condenser covered with gutta-percha is placed in this space and operated. The aim is for the microflow main cone to combine with the microflow gutta-percha on the condenser and obturate the abnormalities in the root canal (Malagnino et al 2011).

3.3. Quickfill

In the Quickfill system, a titanium thermocompactor is used as a transporter for the placement of alpha phase gutta-percha core material into the root canal (Estrada & Lopez, 2018). The carrier thermocompactor is fitted to a low-speed hand operated at 3000-6000 rpm, and when operated in the canal, the heat produced by the contact softens the gutta-percha. Therefore, no additional heating procedure is required. The carrier is placed into the root canal with a clockwise rotation and some pressure, while it is slowly taken out of the root canal with a counter clockwise rotation (Kaplan vd., 2019). The system is not recommended for use in root canals with a high inclination angle (Alaçam, 2012). A study conducted by Gençoğlu in 2003 found that Thermafil, QuickFill and SoftCore were superior to Microseal, System B and lateral condensation techniques regarding gutta-percha/seal ratio.(Gencoğlu, 2003).

4. Solid-Core Techniques

4.1. Thermafil, Profile GT, GT Series X and ProTaper Universal

Guttacore and Thermafill (DentsplySirona Dental Specialties) were presented as guttapercha root canal filling materials having a strong core. Originally produced with a metal core and a gutta-percha coating, the carrier is heated by fire. Core material in the center has become popular because it facilitates the placement of gutta-percha in the root canal (Zogheib et al., 2013). The ease of placement in the canal and the flexible structure of gutta-percha constitute its advantages. The disadvantages are that the metal core makes post placement difficult and retreatment procedures are challenging. Furthermore, gutta-percha frequently remodev from the carrier during root canal filling and remained as a carrier obturator material in the apical part of the canal (Berman ve Hargreaves, 2021). Studies have reported that carrier systems leave minimal voids in the root canal obturation (Zogheib et al., 2013). Studies evaluating healing rates have reported no difference between guttapercha lateral compaction and carrier systems (Hale et al, 2012).

It is reported that Thermafil core carrier supports the root dentin more and contributes to the resistance to fracture of the root compared to cold lateral condensation, single cone technique and continuous heat obturation technique (Ersoy & Evcil, 2015). Since it is heat treated before being placed in the canal, it takes advantage of thermoplasticized gutta-percha and provides a homogeneous filling, but the filling quality decreases in case of intracanal irregularities such as internal resorption (Elenjikal et al, 2019).

According to the reports that the amount of gutta-percha on the carrier may be insufficient to fill the resorption cavity (Gencoglu vd., 2008).

Two innovations made to the carrier systems are the creation of an alpha phase gutta percha coated plastic core and a temperature-controlled heating oven. The obturators are made to fit nickel titanium rotary files of different angles, ISO standard file sizes, and nickel titanium rotary files from the Profile GT and GT series X (DentsplySirona). Dimension choppers are available that passively match the working length to assist in selecting the appropriate carrier (Berman ve Hargreaves, 2021).

The carrier is put inside the oven to heat up. Once the suitable temperature is reached, the clinician has nearly 10 seconds to remove the carrier and place it in the root canal system. The carrier should not be rotated or twisted during this process. Studies have shown that the speed of placement affects the root canal obturation (Levitan et al, 2003). Fast placement increases the quality of the canal filling (Levitan et al., 2003). After this procedure, vertical compaction of coronal gutta-percha can be performed. Gutta percha can be added, heated to soften it and then compressed if needed. The ability of gutta percha to spread into lateral and accessory canals is a benefit of this method (Wolcott et al, 1997). In this case, the material being carried beyond the anatomical apex creates a disadvantage (Nino-Barrera et al., 2018).

Most recently generation core carrier, GuttaCore, interconnected gutta-percha is used as the carrier. An in vitro investigation compared the needed the moment to remove GuttaCore, Thermafil Plus and thermoplastic gutta percha from a comparatively curved root canal system using Pro Taper retreatment files and stated that GuttaCore was removed considerably faster than the other two techniques (Beasley et al, 2013). The healing rates of nonsurgical root canal treatment with the carrier root canal filling technique are similar to those reported for other root canal filling techniques (Pirani et al, 2018).

4.2. SuccessFil

Successfil (Coltene, Whaledent, Cuyahoga Falls) is a carrier system related to Ultra 3D.

This technique's gutta percha is kept in a syringe. Titanium or radiopaque plastic carriers are placed in the syringe to the working length. After the gutta-percha stored in the syringe is softened in small ovens modified for the placement of the syringe, the carrier is placed in the syringe in a way that it will be the measured canal length and is covered with gutta-percha. Depending on the canal morphology, gutta percha can be condensed

around the carrier using different pluggers. Then, the carrier is cut with a bur above the canal entrance (Berman ve Hargreaves, 2021).

4.3. Simplifill

Core carriers are manufactured to be compatible with the Lightspeed rotary file system. The carrier has an apical plug coated with gutta-percha or resilon at the apical 5 mm. After the carrier is slowly inserted into the canal at the working length, the handle is rapidly rotated counterclockwise at least four full turns so that the apical plug remains in place while the carrier is removed from the canal. Next, gutta-percha can be used to fill the coronal section of the canal by either lateral compaction or a warm thermoplastic approach. This cross-sectional technique is effective and the potential for leakage is comparable to other widely used methods (Santos et al., 1999). Since the core carrier material is not left in the root canal, the problems that other carrier-based techniques create when retreatment application and post space creation are not encountered (Kaplan et al, 2019).

5. Thermoplastic Injection Techniques

One of the techniques recommended for filling the root canal after the chemomechanical preparation is to heat and soften the gutta-percha and then place it in the root canal with pressure using specially developed devices. Current devices developed for this technique are: Obtura III, Calamus, Elements, HotShot and Ultrafil 3D. Among them, Ultrafil 3D system uses low temperature gutta-percha heated to 90 ° C, while the others use high temperature gutta-percha heated to 160 ° C (Soo et al., 2015).

Enhanced ability of injectable thermoplasticized gutta percha to fill internal resorption gaps and other imperfection in canals like lateral canals, and C-shaped canals has been reported (Soo et al., 2015). When applying the technique, it is recommended to place a master cone in the apical part to prevent the possibility of overflow filling due to lack of apical control, especially in teeth with wide apexes (Olson et al., 1989).

5.1. Obtura III

The Obtura III system (ObturaSpartan, Fenton, MO) comprises of a hand gun and a control unit, which has a chamber that allows the gutta-percha pellets placed inside to be heated to a minimum of 160 °C thanks to the heating apparatus around it. The system includes silver syringes in sizes 20, 23, and 25 G for placing thermoplasticized gutta-percha into the canal. The temperature of gutta percha and viscosity can be changed by the user using the control unit (Bradshaw et al., 1989).

To avoid apical extrusion in the technique, the diameter of the apical constriction should be prepared as tiny as feasible. It should be applied with gutta-percha paste while filling the canal (Bradshaw et al, 1989). To avoid filling the apex with paste accumulation only, the paste should be applied to the canal walls (Alaçam, 2012). Gutta-percha is preheated and thermoplasticized in the Obtura gun and passively injected into the canal after the silver syringe is placed 3-5 mm from the apical end. As the canal fills, the syringe is withdrawn from the canal and pluggers can then be used to compress the gutta-percha. This compression process should continue until the gutta-percha has cooled and solidified. It has been reported that Obtura adapts well to the root canal and that it will not cause harm to the periodontal ligament, as the temperature increases on the root surface are below the crucial point (TaniIshii et al., 2003).

5.2. Ultrafill 3D

Ultrafill 3D, used for low-temperature thermoplastic injection technique, is a device that supports three different types of disposable gutta-percha cannulas with needles that can be prebeveled based on the root canal shape. It has a transferable heating unit, adjustable regardless of humidity or temperature (Lokhande et al., 2019). Gutta-percha cannulas used in the system; —Regular SetI has low viscosity and hardens in 30 minutes, —Firm SetI also has low viscosity, the difference is that 4 minutes is enough for it to harden. —EndosetI has a high viscosity. Its setting time is 2 minutes. To avoid cavity formation during root canal filling, heated gutta-percha should be injected without applying excessive pressure and the syringe should be allowed to move away from the canal as it fills (Kaplan et al., 2019). A different preparation technique was developed to prevent apical extrusion. In this technique, the canal is enlarged to 3 sizes larger than a file that provides a tight fit at the working length and the canal is enlarged slightly further to allow a 22-gauge needle to be inserted up to 6 mm into the working length. After the canals were filled, the apical extrusion status was examined radiographically and the method was found to be successful (George et al, 1987).

5.3. Calamus

Calamus is an obturation system that combines the —CalamusflowI and —CalamuspackI devices, which allow the simultaneous use of —injectableI and —pumpableI gutta-percha filling material (Ruddle, 2010). The —CalamuspackI handpiece, with a suitably sized electric heating plugger, is used to soften the gutta-percha by heat, remove excess from the canal, and condense it when filling the apical part of the canal. The electric

heating pluggers come in 3 sizes and are selected based on the curvature, taper and apical dimension of the finished root canal preparation.

The Calamuspack handpiece can also be used to perform a diagnostic —hot test on the heat-sensitive pulp tissue (Gupta et al., 2015). The —CalamusFlow handpiece, with a one-piece guttapercha cartridge and a compatible cannula, is used to inject warm gutta-percha during the obturation phase of the coronal and middle thirds. The cartridges come in gauge sizes of 20 and 23 and are intended for single use only. There is also a bending tool available to pre-bend the cannula in curved root canals (Gupta et al., 2015). The temperature at which thermoplasticized gutta-percha is extruded from the needle tip varies between 38°C and 44°C. Depending on the viscosity of the gutta-percha, it continues to flow for 45-60 s (Jain, 2016).

5.4. HotShot

HotShot, one of the devices used for thermoplastic injection technique, allows the guttapercha to be heated to 150-230 °C. The device looks like a composite gun, is cordless and lightweight. It is appropriate for use with gutta-percha or resilon. The needles used for the injection of heated filling material are available in sizes 20, 23 and 25. Similar to other thermoplastic injection devices, it has been suggested for use in filling anatomical irregularities such as internal resorption (Shenoi et al, 2014).

5.5. Elements

The device, which combines the downpack and backfill units and is designed wirelessly, provides freedom of movement during treatment. The temperature value, which can be adjusted between 100 and 400 °C, allows the most suitable temperature for the filling material used to be set in a short time such as 0.5 seconds. The 360° activation ring on the downpack device, the prebeveled needle tips and the extrusion effect of the backfill device ensure that gutta-percha is placed in the root canal efficiently, easily and precisely, without leaving any gaps (Bey et al., 2015).

Gutta-percha cartridges are single-use, eliminating the risk of cross-infection. Both handpieces in the unit have a silicone boot that acts as an insulator to prevent heat transfer and protects the clinician's hands during treatment. The needle tips that deliver the thermoplastic gutta-percha to the canal are 20-, 23- and 25-gauge and are pre-beveled. The activation ring on the downpack handpiece gives off heat when pressed, and thanks to its timeout feature, if it is not activated within 4 seconds, it is deactivated, preventing excessive heat from being transmitted to the tissues (Bey et al., 2015).

It has been reported that a homogeneous filling can be achieved with minimal void formation and provides advantages in intricate canal morphologies such as C-shaped root canals. (Eren et al 2017; Gok et al2017).

6. Future Technology and Nanodiamond Content Gutta-percha

Clinical trials on gutta-percha containing nanodiamonds are progressing promisingly and no adverse effects have been reported (Lee, et al. 2017). These studies may form the basis for ongoing clinical research on nanodiamond biomaterials and endodontic applications (Berman ve Hargreaves, 2021). Particles smaller than nanometers are employed in several branches of medicine. Among the many applications of nanoparticles in biomedicine are drug administration, protein transport, and imaging. Additionally, surgical instruments like implants and graft materials can benefit from the use of nanoparticles to enhance their mechanical characteristics and bioactivity (Najeeb vd., 2016).

NDs have a variety of uses in medicine. Additionally, they can be utilized as nanofillers to enhance the mechanical characteristics of composite polymers. Recently in dental components include the integration of nanoscale particles and surface modifications to enhance the mechanical and biological attributes of dental implants, guiding restorative materials, and resources for tissue regeneration (Passeri et al, 2015). Nanoscale fillers like silica and alumina to enhance technical and visual attributes, as well as bioceramics and bioglass materials like hydroxyapatite (HA) and fluorohydroxyapatite (FHA) for implant alteration and directed tissue repair, are a few instances of nanoscale particles used in dentistry. Antibacterial NDs reinforced gutta-percha has been considered as a potential endodontic substance (Lee et al, 2015).

A restorative material is inserted into the root canal to seal (or fill) it after it has been cleaned and shaped. Traditionally, rubber-based gutta-percha has been used as the endodontic material of selection because of its ease of removal and radiopacity. Nevertheless, in most situations, standard endodontic materials are unable to thoroughly disinfect the canal due to their poor mechanical qualities and leaking, and infection may persist despite the obstruction (Lee et al, 2015).

In a study, Lee et al. successfully combined amoxicillin (NDamoxicillin)-linked NDs with GP and found that the composite ND GP increased yield strength, tensile strength, and Young's modulus in addition to exhibiting enhanced bactericidal properties against Streptococci through sustained medication release (Fouad & Torabinejad, 2008). This study could be the first of many that could lead to the growth of endodontic materials that carry regenerative growth factors to provide root and pulp dentin

regeneration as well as the delivery of antibiotics to the canal. Although these NDs have not yet been observed in vitro, human dental pulp cells cultivated on oxygenated NDs exhibited improved growth and distinction additionally to the creation of mineralized tooth tissue, suggesting the possibilities of NDs to regenerate teeth. (Duailibi et al., 2013).

In the light of this information, the ensuing findings can be reached; It is known that the root canal obturation makes a significant contribution to the success of endodontic treatment.

There is not much data to back one up filling method in preference to another. Every technique offers benefits and drawbacks. Doctrine should not guide decision-making; rather, the clinical scenario should. Thus, having a thorough understanding of the available possibilities aids the doctor in selecting the best method for the tooth being treated.

References

- Guimaraes BM, Silva PAA, Alcalde MP, Marciano MA, et al.A. (2014). Influence of ultrasonic activation of 4 root canal sealers on the filling quality. . *Journal of endodontics*, 40(7):964-8.
- Chevigny C, Dao TT, Basrani BR, Marquis V, Farzanah M, et al. (2008). : Treatment outcome in endodontics: the Toronto study—phases 3 and 4: orthograde retreatment. *J Endod*, 34: 131-137.
- Peng L, Ye L, Zhou X. (2007). Outcome of root canal obturation by warm gutta-percha versus cold lateral condensation: a meta-analysis. *J Endod*, 33: 106-109.
- Gordon MPJ, Love RM, Chandler NP. (2005). An evaluation of .06 tapered gutta-percha cones for filling of .06 taper prepared curved root canals. *International endodontic journal*, 38(2):87-96.
- Schäfer E, Nelius B, Bürklein S. (2012). A comparative evaluation of gutta-percha filled areas in curved root canals obturated with different techniques. *Clinical oral investigations*, 16(1):225- 30.
- Pereira AC, Nishiyama CK, Pinto LC. (2012). Single-cone obturation technique: a literature review. *RSBO Revista sul-brasileira de odontologia*, 9(4):442-7.
- Monticelli F, Sadek FT, Schuster GS, Volkmann KR, et al. (2007). Efficacy of two contemporary single-cone filling techniques in preventing bacterial leakage. *Journal of endodontics*, 33(3):310-3.
- Cailleteau JG, Mullaney TP. (1997). Prevalence of teaching apical patency and various instrumentation and obturation techniques in United States dental schools. *J Endod*, 23: 394396.
- Zmener O, Banages G. (1999). Clinical experience of root canal filling by ultrasonic condensation of gutta-percha,. *Endod Dent Traumatol*, 15: 57-59.
- Frantzeska K. (2017). Gutta Percha and Updated Obturating Techniques. *Journal of dental health oral disorders & theraphy*, 8(2):00276.
- Alaçam, T. (2012). kök kanal dolgu yöntemleri. *endodonti*, 1332.
- López, Estrada V. (2018). Do Thermoplastic Materials Improve the Obturation of the Root Canal? Bibliographic Review of the Different Techniques Available in the Market. *Journal of dental health oral disorder theraphy*, 9(1):00323.
- Pişkin B, Aydın B, Sarıkanat M. (2008). The effect of spreader size on fracture resistance of maxillary incisor roots. *International endodontic journal*, 41(1):54-9.
- Punia SK, Nadig P, Punia V. (2011). in vitro assessment of apical microleakage in root canals obturated with gutta-flow, resilon, thermafil and lateral condensation: A stereomicroscopic study. *J Conserv Dent*, 14:173–7.

- Elayouti A, Achleithner C, Löst C, Weiger R. (2005). Homogeneity and adaptation of new gutta percha paste to root canal walls . *J Endod.*, 31:687-90.
- SCHILDER, H. (1964). Endodontic therapy. Current therapy in Dentistry. *The C.V. Mosby Company, St. Louis.*, 2:84.
- Tomson RME, Polycarpou N, Tomson PL.(2014). Contemporary obturation of the root canal system. *British dental journal*, 216(6):315.
- Keleş A, Alcin H, Kamalak A, Versiani MA. (2014). Micro-CT evaluation of root filling quality in oval-shaped canals. *International endodontic journal*, 47(12):1177-84.
- Suguro H, Takeichi O, Hayashi M, Okamura T, Hira A, Hirano Y et al. (2018). Microcomputed tomographic evaluation of techniques for warm gutta-percha obturation. *Journal of oral science*, 17-0092.
- Brothman P. (1981). A comparative study of the vertical and the lateral condensation of gutta- percha. *Journal of endodontics*, 7(1):27-30.
- Blum JY, Esber S, Micallef JP. (1997). Analysis of forces developed during obturations. Comparison of three gutta- percha techniques. *J endod*, 23: 340-345.
- Kytridou V, Guttman JL, Nunn MH. (1999). Adaptation and sealability of two contemporary obturation techniques in the absence of the dentinal smear layer. *Int Endod J*, 32: 464-474.
- Cen R, Wang R, Cheung GSP. (2018). Periodontal Blood Flow Protects the Alveolar Bone from Thermal Injury during Thermoplasticized Obturation: A Finite Element Analysis Study. *Journal of endodontics*, 44(1):139-44.
- Clinton K, Himel TV. (2001). Comparison of a Warm Gutta-Percha Obturation Technique and Lateral Condensation. *JOURNAL OF ENDODONTICS*.27(11):692-5.
- Jain P (2016). Current therapy in endodontics. *John Wiley & Sons*.
- Liewehr FR, Kulild JC, Primack PD. (1993). Improved density of gutta-percha after warm lateral condensation. *JOE*, 19(10):489-9.
- Martin H, Fischer E. (1990). Photoelastic stress comparison of warm (Endotec) versus cold lateral condensation techniques. *Oral surgery, oral medicine, oral pathology.*, 70(3):325-7.
- Castelli WA, Caffesse RG, Pameijer CH, Perez RD, Farquar J (1991). Periodontium response to a root canal condensing device (Endotec). *Oral surgery, oral medicine, oral pathology.*, 71(3):333-7.
- Pagavino G, Giachetti L, Nieri M, Giuliani V, Russo DS. (2006). The percentage of gutta-percha- filled area in simulated curved canals when filled using Endo Twinn, a new heat device source. *International endodontic journal*, 39(8):610-5.

- Kulild J, Lee C, Dryden J, Collins J, Feil P. (2007). A comparison of 5 gutta-percha obturation techniques to replicate canal defects. *Oral surgery, oral medicine, oral pathology, oral radiology, and endodontology*, 103(1):e28-e32.
- Kaplan T, Kaplan SS, Öveçoğlu HS. (2019). Güncel Kök Kanal Dolum Teknikleri. *Türkiye klinikleri endodonti-özel konular*, 5(2):18-24.
- Berman LH, Hargrevas KM. (2021). Cohen's pathways of the pulp expert consult. *Elsevier Health Sciences*, 280-316.
- Nahmias Y, Mah T, Dovgan JS. The thermohydraulic condensation technique. (2001) *Oral Health*, 11-14.
- Leonardo MR, Cervi DA, Tanomaru JMG, Silva LAB. (2004). Effect of different rotary instrumentation techniques and thermoplastic filling on apical sealing. *J Appl Oral Sci*, 89-92.
- EM, S. (1989). The effect of variation in thermomechanical compaction techniques upon the quality of the apical seal. *Int Endod J*, 22: 163-168.
- EM, S. (1990). In vivo findings associated with heat generation during thermomechanical compaction of gutta-percha. 2. Histological response to temperature elevation on the external surface of the root. *Int Endod J*, 268-274.
- Malagnino VA, Fedele GR, Passairello P, Canullo L. Simultaneous technique and a hybrid microseal / pacmac obturation. *Endodontics 2011*;477-484.
- Estrada MM, Lopez IB. (2018). Do Thermoplastic Materials Improve the Obturation of the Root Canal? Bibliographic Review of the Different Techniques Available in the Market. *Journal of dental health oral disorder therapy*, 9(1):00323.
- Gencoglu N, Yıldırım T, Garip Y, Karagenç B, Yılmaz H (2008). Effectiveness of different gutta-percha techniques when filling experimental internal resorptive cavities. *IEJ*, 41(10):836-42.
- Zogheib C, Naaman A, Sigurdson A, Medioni E, et al (2013). Comparative micro-computed tomographic evaluation of two carrier-based obturation systems. *Clin Oral Investig*, 18791883.
- Hale R, Gatti R, Glickman GN, Opperman LA. (2012). Comparative analysis of carrierbased obturation and lateral compaction. *Int J Dent*, 954675.
- Ersoy I, Evciloğlu MS. (2015). Evaluation of the effect of different root canal obturation techniques using two root canal sealers on the fracture resistance of endodontically treated roots. *Microscopy research and technique*, 78(5):404-7.
- Elenjikal MJ, Latheef AA, Kader MAM, Ganapathy S, et al. (2019). A comparative evaluation of five obturation techniques in the management of simulated internal resorptive cavities. *Journal of pharmacy & bioallied sciences*, 11.
- Levitan ME, Himel VT, Luckey JB (2003). The effect of insertion rates on fill length and adaptation of a thermoplasticized gutta-percha technique. *J Endod*, 505-508.

- Nino-Barrera JL, Gamboa-Martinez LF, Laserna-Zuluaga H, et al. (2018). Factors associated to apical overfilling after a thermoplastic obturation technique- Calamus or guttacore. A randomized clinical experiment. *Acta Odontol Latinoam*, 45-52.
- Wolcott J, Himel VT, Powell W, Penney J. (1997). Effect of two obturation techniques on the filling of lateral canals and the main canal. *J Endod*, 23:632-635
- Beasley RT, Williamson AE, Justman BC, Qian F. (2013). Time required to remove guttacore, thermafil plus, and thermoplasticized gutta-percha from moderately curved root canals with protaper files. *J Endod*, 39: 125-128.
- Pirani C, Friedman S, Gatto MR, Iacono F, et al. (2018). Survival and periapical health after root canal treatment with carrier- based root fillings. *five-year retrospective assessment, Int Endod J Suppl* 3, 51: e178- e188.
- Santos MD, Walker WA, Carnes DL. (1999). Evaluation of apical seal in straight canals after obturation using the Lightspeed sectional method. *JOE*, 25(9):609-12.
- Soo WKM, Thong YL, Gutmann JL. (2015). A comparison of four gutta-percha filling techniques in simulated C-shaped canals. *International endodontic journal.*, 48(8):736-46.
- Olson AK, Hartwell GR, Weller RN. (1989). Evaluation of the controlled placement of injected thermoplasticized gutta-percha. *JOE*, 15(7):306-9.
- Bradshaw GB, Hall A, Edmunds DH. (1989). The sealing ability of injection-moulded thermoplasticized gutta-percha. *International endodontic journal.*, 22(1):17-20.
- Tani-Ishii N, Terenaka T. (2003). Clinical and radiographic evaluation of root-canal obturation with obtura II. *Journal of endodontics.*, 29(11):739-42.
- Lokhande PR, Ghorpade R, Srinidhi SR. (2019). A Review of Contemporary Research on Root Canal Obturation and Related Quality Assessment Techniques. *Innovative Design, Analysis and Development Practices in Aerospace and Automotive Engineering (I-DAD 2018)*. Springer, 511-25.
- George JW, Michanowicz AE, Michanowicz JP . (1987). A method of canal preparation to control apical extrusion of low-temperature thermoplasticized gutta-percha. *JOE*, 13(1):18-23.
- Ruddle. (2010). Filling root canal systems: the Calamus 3-D obturation technique. *Dentistry today.*, 29(76):78-81.
- Gupta R, Dhingra A, Panwar N. (2015). Comparative evaluation of three different obturating techniques lateral compaction, Thermafil and Calamus for filling area and voids using cone beam computed tomography:. *Journal of clinical and diagnostic research*, 9(8):ZC15.
- Jain P. (2016). Current therapy in endodontics. *John Wiley & Sons*.

- Shenoi PR, Makade C, Kubde R, Badole GP. (2014). Comparative evaluation of different techniques used to obturate experimental internal resorptive Defects-An in vitro study. *Endodontology*, 26:286-90.
- Bey GL. (2015). A Complicated Endodontic Retreatment Using A New Cordless Obturation System: A Case Report. *Oral health dental journal.*, 16:26.
- Eren SK, Örs SA, Yılmaz Z. (2017). Effect of Post Space Preparation on Apical Obturation Quality of Teeth Obturated with Different Techniques: A Micro-computed Tomographic Study. *Journal of endodontics.* , 43(7):1152-6.
- Gok T, Capar ID, Akçay I, Keleş A. (2017). Evaluation of different techniques for filling simulated C-shaped canals of 3-dimensional printed resin teeth. . *Journal of endodontics.*, 43(9):1559-64.
- Lee DK, Kee T, Liang Z, Hsiou D, Miya D, et al (2017). Clinical validation of a nanodiamond-embedded thermoplastic biomaterial. *Proc Natl Acad Sci U S A*, E9445- E9454.
- Lee DK, Kim SV, Limansubroto AN, Yen A, Soundia A, et al. (2015). Nanodiamond-gutta percha composite biomaterials for root canal therapy. *ACS Nano* , 9: 11490-11501.
- Duailibi S, Duailibi MT, Ferreira LM, Carvalho KI, et al. tooth tissue engineering: the influence of hydrophilic surface on nanocrystalline diamond films for human dental stem cells. 2013;19:23-24

CHAPTER 3

CURRENT IRRIGATION ACTIVATION METHODS

Büşra Nur ERGÜL¹

Beyza TURAN SAĞLAM²

Selen İNCE YUSUFOĞLU³

1 Department of Endodontics, Faculty of Dentistry, Ankara Yıldırım Beyazıt University, Ankara, Turkey ORCID: 0009-0005-3679-226X

2 Department of Endodontics, Faculty of Dentistry, Ankara Yıldırım Beyazıt University, Ankara, Turkey ORCID: 0009-0007-1728-511X

3 Department of Endodontics, Faculty of Dentistry, Ankara Yıldırım Beyazıt University, Ankara, Turkey ORCID: 0000-0002-7826-6023

GENERAL INFORMATION

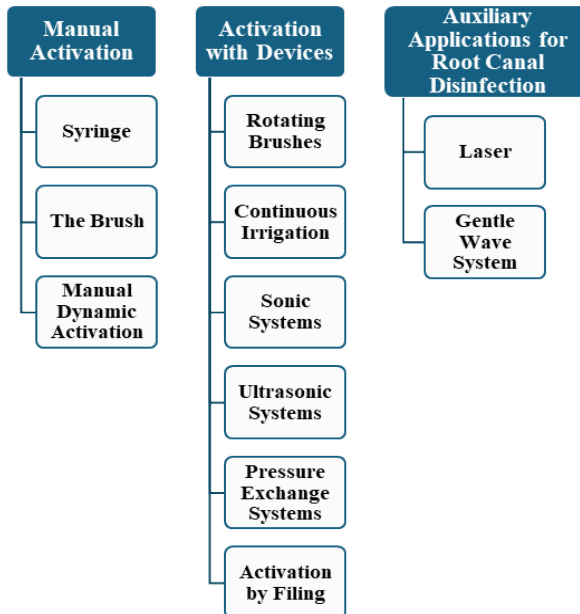
The objective of endodontic treatment is to eliminate all essential and nonvital tissues that are home to microorganisms in the root canal to able to rid the system of bacteria and their byproducts, which are the cause of infection (Dornelles-Morgental et al., 2011).

The two most crucial phases of a successful root canal therapy are chemical irrigation and mechanical preparation. The best method for cleaning parts of the root canal walls that are inaccessible by mechanical preparation is to irrigate the system (Haapasalo et al., 2010).

Despite the use of rotary systems for root canal shaping, most of the shaping is concentrated in the center of the canal, but it is not possible to access and effectively clean areas such as the lateral canal and isthmus (Mohammadi et al., 2021; Önay EO et al., 2013). Since these areas are suitable locations for debris, microorganisms and their by-products and do not allow adequate adaptation of canal filling materials, they may cause recurrent periapical infections. Therefore, irrigation has a significant part in the cleaning of root canals in addition to root canal shaping (Basrani et al., 2003; Meltem Küçük et al., 2016; Vineet et al., 2014).

Various irrigation solutions are used for irrigation in root canals. Many irrigation solutions such as NaOCl, EDTA, CHX, HEBP, REDTA, Rc-Prep, Citricacid, Tannicacid, Qmix, MTAD, Irritrol are currently used.

IRRIGATION ACTIVATION METHODS



MANUAL ACTIVATION TECHNIQUES

Conventional Needle Irrigation

In this method, irrigation solutions are applied by moving up and down the root canals with needles or cannulas of various diameters. Some of the needle tips dispense the solution from their distal stops, while others dispense through side cavities with closed tips (ProRince, Max-I-Probe), which are designed to reduce the possibility of apical extrusion of irrigation solutions and increase hydrodynamic activation (Hauser et al., 2007). The free movement of the needle during irrigation without getting stuck in the canal is important in terms of allowing the irrigation to back out and displacing more debris in the coronal direction, as well as preventing the undesirable effects that may occur when the irrigation solution extrude into the periapical tissues (Van Der Sluis et al., 2006).

As a result, there is a limited depth of penetration for the irrigation fluid and dentinal tubule disinfection (Langeland et al., 1985). It was proposed that the effectiveness of syringe irrigation can be increased by utilizing a smaller diameter needle tip, bringing the needle tip closer to the apex, and increasing the volume of irrigation fluid (Sedgley et al., 2004). The likelihood of the irrigation fluid extruding into the apical tissues is increased by the needle tip's close contact to the apical tissues. Continuous hand movements and slow release of the solution minimize NaOCl accidents (Ram, 1977).

Plastic propylene tips (Irriflex, 30G-27 mm), (Trunatomy, 30G-28 mm) were produced because of the difficulties encountered in sending metal irrigation tips to the apical region. Due to their flexible structure, they can deliver irrigation solution to the apical region without getting stuck in the root canal walls (Gao et al., 2009).

Brushes

Brush-covered needles are instruments for pulp debris removal and irrigation activation in endodontics. Endobrush (C & S Microinstruments Limited, Markham, Ontario, Canada) with spiral-shaped brushes made of nylon bristles between twisted wires and NaviTip FX (UltradentProductsInc, South Jordan, UT) brushes with a 30 gauge irrigation needle covered with a brush have been developed for use in endodontic practice (Önay EO et al., 2013; Pesse et al., 2005a). A study found that the coronal part of root canal walls irrigated, instrumented, and treated with NaviTip FX (UltradentProductsInc, South Jordan, UT) were cleaner than those treated with brushless syringes, but no statistically significant difference was detected in the middle and apical parts (Zmener et al., 2009).

In the another study by Keir et al., the Endobrush was used for 1 min at the end of the instrumentation with a 2-3 mm push-pull motion combined with a 90-degree rotation for the study length. The study showed that root canal cleaning with Endobrush was superior to that without Endobrush (Keir et al., 1990). In addition, the Endobrush may not reach the entire working length due to its thickness, which may result in debris being pushed into the apical area after brushing (Al- Hadlaq et al., 2006).

Manual Dynamic Activation (MDA)

The irrigation solutions need to enter direct contact with the canal walls in order for root canal therapy to work. Nevertheless, due to the “vapor-lock effect,” which is an air bubble that forms in the apical area, irrigation solution storage is typically challenging (Pesse et al., 2005b). It is a method in which the solution is advanced to the apical region by moving the gutta percha, which is selected as the master cone in the expanded teeth, 2-3 mm back and forth in the working size of the canal (Canavar T et al., 2020). The reciprocating movement of the gutta percha compatible with the root canal 90 times in 30 seconds creates variable pressure areas within the canal and brings the irrigation agent into contact with more surfaces (Canavar T et al., 2020).

ACTIVATION TECHNIQUES WITH THE DEVICES

Brushes Used with Rotary System

One of the first rotary brushes produced was the Microbrush. It consists of two parts, a handle and a brush. During canal cleaning and shaping, the microbrush rotates at 300 rpm, causing debris to move in the coronal direction and is carried out of the root canal (Gu et al., 2009). Another endodontic rotary brush is the Canal Brush (ColteneWhaledent, Langenau, Germany). This highly flexible microbrush is manually rotated and is made entirely of polypropylene. However, it performs better when paired with an inverted angle rotary instrument running at 600 rpm (Gu et al., 2009).

Continuous Irrigation During Rotary System Instrumentation Quantec-E

The irrigation system (SybronEndo, Orange, USA) includes self hydration unit connected to the Quantec-E Endo. During rotational system instrumentation, the system’s two solution tanks, a pump tip, and tubes assure continual irrigation (Walters et al., 2002). Syringe irrigation and the Quantec-E system were compared in the Setlock et al. study, and the results

showed that there was a difference in the coronal part of the root in terms of debris and smear layer removal as well as cleaning of the canal walls, but no difference in the middle and apical parts of the roots (Setlock et al., 2003).

Self Adjusting File (SAF)

It is a system consisting of a single file that can shape the root canals and perform three-dimensional the root canals' shape and cleansing. SAF (Re-Dent-Nova, Ra'anna, Israel) is the single file without a solid metal core, eliminating the risk of instrument breakage during shaping (Çakıcı et al., 2019). The SAF is a hollow shaping file with a lace-like weave of Ni-Ti alloy on the outside. The lace-shaped wire is coated with 120 µm thick nickel titanium (Çakıcı et al., 2019).

SAF is 1.5 or 2 mm in diameter. It includes a file (CourtesyReDent-Nova, Raanana, Israel), a head (Kavo, BiberachRiss, Germany) and a unique irrigation apparatus (VATEA, ReDent, Raanana, Israel) (Meltem Küçük et al., 2016). While all irrigation activation systems are based on increasing the flow movement of the solution and inducing acoustic flow, SAF mechanically cleans the dentin surface (Metzger, 2014). There is a panel on the device that allows the flow rate to be controlled. The flow rate can vary between 1-10 mL per minute. It is recommended to be used for 4- 5 minutes in each root canal. Since SAF is a file system made of Ni-Ti with a reticulated structure, it has been shown that this file Works by expanding on long oval root canal walls and successfully cleans both round and oval canal systems (Peters et al., 2001).

In a micro-computed tomography (MCT) study, a conventional rotary file system and SAF were used to shape the mesiobuccal canals of maxillary molars and it was found that the SAF system was superior than other rotary system (El Ashiry & Farsi, 2018). The SAF system's antibacterial efficacy was shown to be more effective than traditional needle irrigation in a microbiologic research (De-Deus et al., 2011).

Irrigation with Alternating Pressure

It is an irrigation method supported by negative and positive pressure method. The devices work by creating sequential regular pressure (Önay EO et al., 2013).

EndoSafeSystem

The Endo Safe system (VPro; Vista Dental, Racine, WL, USA) uses the unit's suction cup through a special connection in addition to the con-

ventional needle. Since it allows more irrigation solution to enter the canal than conventional irrigation, it is theoretically expected to clean more (Desai & Himel, 2009). Sarno et al., however, reported that when it came to cleaning the apical portion of the root on molar teeth, they could not find a statistically significant difference between the EndoSafe system and traditional needle irrigation (Sarno et al., 2012).

RinsEndo

RinsEndo (Dürr Dental GmbH & Co KG, Bietigheim-Bissingen, Germany) is an automatic- dynamic irrigation activation device that works by using the positive pressure generated by the unit (Önay EO et al., 2013). The unit consists of an attached head, injector or and cannula. In this technology, 65 microliters of solution is drawn from the injector connected to the system at a vibration frequency of 1.6 Hz and communicated to the canal through the probe (Önay EO et al., 2013). In these condephase, it draws the irrigation solution back from the root canal with the effect of vacuum. The biggest disadvantage of the device is the risk of apical extrusion the solutions from the apical foramen because it works with positive pressure (Önay EO et al., 2013). In their study, Desai and Himel found that RinsEndo extruded more solution from the apical foramen than EndoVac and Endoactivator systems (Desai & Himel, 2009).

Toljan et al. examined the effects of RinsEndo and passive ultrasonic irrigation (PUI) on *E. Faecalis* biofilm (Toljan et al., 2016). As a result of the study, RinsEndo was found to be significantly more effective than PUI on *E. Faecalis* biofilm in groups in which irrigation solution volume was kept constant (Toljan et al., 2016). Vivan et al., however, found no statistically significant difference in debris removal between the RinsEndo method and traditional needle irrigation (Vivan et al., 2010).

EndoVac

Negative pressure is used in the EndoVac irrigation activation system (Discus Dental, Culver City, CA) (Gu et al., 2009). The aspirator of the dental unit provides the negative pressure. It is a system consisting of a micro probe, macro probe and a master delivery tip. During irrigation, the micro cannula is placed in the apical third of the canal, while the macro cannula is placed in the coronal part of the roots (Gu et al., 2009). In this way, the irrigation solution given to the entrance cavity is directed to wards the apical with a negative pressure and is absorbed by the microcannula from the apical side and removed from the root canal system (Dunavant et al., 2006). The macro cannula is responsible for removing larger debris in the coronal region (Gu et al., 2009). The biggest advantage of the system

is that it can perform an effective canal cleaning up to the working length by preventing extrusion of the solution into the periapical tissues. In a study in which different irrigation activation techniques were used, Yılmaz et al. reported that EndoVac and RinsEndo groups were not more effective than other groups in smear layer removal (Yılmaz et al., 2017). However, Thulaseedharan et al. reported that EndoVac system was more effective than conventional needle irrigation and PUI in the removal of *E. Faecalis* from root canals (Thulaseedharan et al., 2020).

Sonic Devices

Sonic systems work with vibrations in the horizontal direction without rotational movement at a frequency of 2-3 kHz. Sonic irrigation differs from ultrasonic irrigation in terms of creating a smaller shear force and working with a lower frequency (1-6 kHz) (Ahmad et al., 1987).

EndoActivator

It is a sonic irrigation system with a battery-powered portable hand held unit with three different speed settings (Toljan et al., 2016). The manufacturer states that the frequencies as 33 Hz, 100 Hz and 167 Hz. The system has three different types of disposable polymer tips of different sizes and colors (yellow 15\02, red 25\04, blue 35\04) (Toljan et al., 2016). Since the tips are flat, they do not cut dentin (Toljan et al., 2016). The EndoActivator (DentsplyTulsa Dental Specialties, Tulsa, USA) system has been reported to remove the biofilm layer in the inclined root canal of molars, remove debris in the lateral canals and remove the smear layer (Caron, 2007). When the polymer tip is activated, a debris cluster can be observed in the liquid-filled pulp chamber.

The combination of the vibration of the tip and the short vertical up-and-down movement synergistically creates a strong hydrodynamic motion. In general, 10000 cycles per minute is the cycle at which cleaning is optimized and removal of biofilm and smear layer is effectively achieved (Tomson & Simon, 2016). According to Karade et al., EndoActivator outperformed traditional syringe irrigation in removing the smear layer (Karade et al., 2018). De Gregorio et al. reported that there was no statistically significant difference between the EndoActivator system and PUI in terms of efficiency in terms of reaching the irrigation solution to the lateral canals 2-4.5 mm behind the apical part when EDTA was used (de Gregorio et al., 2009).

However, Merino et al., found that when it came to the irrigation solution getting to the apical portion of curved and irregularly shaped root

canals, ultrasonic irrigation worked better than the Endoactivator method (Merino et al., 2013).

Vibringe

The Vibringe irrigation system (Vibringe B.V, Amsterdam, The Netherlands) is made out of a disposable 10 ml nylon syringe that can hold a battery-operated piston and pump ring. The device has an irrigation needle attached that is the proper size for root canal preparation (Urban et al., 2017). When the irrigation solution is manually introduced into the root canal system, the vibration of the irrigation needle starts simultaneously. According to the manufacturer's data, the frequency of agitation is reported as 150 Hz (Urban et al., 2017).

Studies show that both Vibringe and Endo Activator systems work better than conventional syringe irrigation in terms of debris removal effect (Urban et al., 2017). Rödiger et al. reported that the Vibringe system cleaned the apical parts better than syringe irrigation, but ultrasonic irrigation provided more effective cleaning of the entire root canal than Vibringe and syringe irrigation (Rödiger et al., 2010).

SonicAir MM 1500

The SonicAir MM 1500 (Micro Mega, Prodonta, Geneva, Switzerland) works with a stainless steel RispiSonic file with a barbed appearance in the frequency range 1500-3000 Hz. The file is designed to both abrade dentin and activate irrigation (Meltem Küçük et al., 2016).

EDDY

A gadget called EDDY; (VDW, Munich, Germany) uses a frequency of 6000 Hz to operate non-cutting polymer tip (Donnermeyer et al., 2019). In 2017, Urban et al. looked at how well various irrigation activation techniques removed dirt and smear layers. According to the one study, Eddy produced outcomes that were comparable to PUI (Urban et al., 2017). Conde et al. compared the effectiveness of PUI and sonic systems in the removal of organic tissues. As a result of the study, they reported that irrigation activation systems were effective in organic tissue removal, but the system did not significantly differ from one another (Conde et al., 2017). When Salas et al. examined the efficiency of several activation techniques for CHX penetration into dentin tubules, they discovered that EDDY outperformed traditional needle irrigation, but they suggested that it was not as effective as PUI (Salas et al., 2021).

Yusufoglu et al. compared the amount of apical debris extrusion in curved root canals using different activation techniques. As a result of the study, the Eddy group had the highest debris extrusion (İnce Yusufoglu et al., 2020). Although PUI provided reduced debris extrusion, no significant difference was seen between PUI, PIPS and MI methods (Merino et al., 2013). Gündoğar et al. investigated the effect of conventional irrigation, EndoActivator, Eddy and PUI on postoperative pain. At the end of 24 hours, the highest pain was found in conventional syringe irrigation, while the lowest pain was found in the Eddy group (Gündoğar et al., 2021).

Ultrasonics

Ultrasonic energy generates a greater frequency at a smaller amplitude than sonic energy. The ultrasonic frequency of 25-30 kHz, which is above the range of human hearing, is what causes the tips to oscillate (above 20 kHz) (Walmsley & Williams, 1989). The ultrasonic tip placed in the canal exhibits activity with horizontal oscillation by creating “node” and “anti-node” zones along the length of the tip (Van Der Sluis et al., 2007). Node represents the minimum displacement or minimum oscillation region, while antinode represents the maximum displacement or maximum oscillation region. In the literature, two varieties of ultrasonic irrigation have been described (Van Der Sluis et al., 2007).

Passive Ultrasonic Activation (PUI)

It is a passive method that only activates irrigation after root canal expansion and does not remove material from the root canal walls (Van Der Sluis et al., 2007). In the passive ultrasonic irrigation method, acoustic energy is transmitted into the root canal by means of an instrument or a thin wire. Ultrasonic energy creates acoustic waves and cavitations in the irrigation solution and increases the contact of the irrigation solution with areas and surfaces not touched by root canal instruments (Van Der Sluis et al., 2007). When Donner-meyer et al. used several ways to take out calcium hydroxide from artificial root canals, they discovered that PUI was statistically substantially more effective than both XP Endofinisher and standard needle irrigation (Donnermeyer et al., 2019).

XP-EndoFinisher File

Recently, the XP EndoFinisher (XPF;FKG Dentaire SA, La Chaux-de-Fonds, Switzerland) was presented as an adjuvant method to enhance irrigation efficacy in endodontics. An ISO 25/.00 instrument, the XPF

is made with NiTi MaxWire (Martensite-AusteniteElectropolish- FleX, FKG) a unique alloy (Bao et al., 2017).

When the file is cooled, it is flat in the M (martensite) phase; when in contact with body temperature, it turns to the A (austenite) phase, while its length decreases from 10 mm to 6 mm apically, and its diameter increases from 1 mm to 1.5 mm and takes the shape of a spoon (Bao et al., 2017).

It is advised to employ irrigation solutions at 800 rpm following the preparation of root canals larger than size 25 (Bao et al., 2017). According to a study, XP-EndoFinisher outperformed PUI and conventional needle irrigation in removing the biofilm layer from the apical region of the root canal (Bao et al., 2017).

Auxiliary Applications for Root Canal Disinfection Laser Activation Techniques

Many lasers (wavelengths from 532 nm to 10600 nm) used experimentally or clinically in dentistry have bactericidal properties due to their thermal effects that cause changes in bacterial cell structure (Beer et al., 2012; Schoop et al., 2006).

Water molecules expand and contract due to the laser's heat effect, creating secondary cavitation in the intracanal fluid (Akyüz Ekim & Erdemir, 2015).

It was discovered that the Er:YAG laser wavelength worked best for creating cavitation bubbles and facilitating fluid circulation in small lateral canals (Weller et al., 1980).

PIPS (Photon Induced Photoacoustic Streaming)

PIPS is an irrigation system that uses an Er:YAG laser to activate irrigation solutions in an indirect manner, eliminating direct contact and heat. (Peters et al., 2011). The PIPS tip is a tapered fiber tip stripped 3 mm from the distal end with a polyamide sheath (Peters et al., 2011). The mechanism of action is to create a powerful photo acoustic pulse wave that flows three-dimensionally through the root canal system with irrigation solutions. The pulp chamber is filled with fluid, and the laser pulses are sent into it using the fiber tip. The fluids take up the Er:YAG light wave. Upon instantaneous local heating of the liquid to boiling point, a vapor bubble forms at the fiber optic tip. The vapor bubble first expands, reaches its maximum volume and then collapses. The collapse initiates the growth of a secondary bubble. The fluid is pumped out of the canals and moved three dimensions through the root canal system by this photoacoustic activation of solutions (Peters

et al., 2011). Unlike other conventional laser applications, the conical PIPS tip just needs to be inserted into the pulp chamber—not the canal system itself (Peters et al., 2011). This technique utilize slow energy levels of 20-50 microjoules (mJ) at a frequency of 10-15 Hz at 0.6 W energy with pulses of only 50 micro seconds duration (Peters et al., 2011). In order to efficiently reach the isthmuses, lateral canals, and apical third of the canal with irrigation solutions during treatment, this lessens the need to employ larger hand files and/or rotary devices to produce larger canal shapes. The penetration of various root canal sealers into dentinal tubules following varying irrigation activation procedures was examined by Akçay et al. They discovered that the bioceramic-based root canal sealer penetrated deeper into dentinal tubules following the application of PIPS and PUI (Akçay et al., 2016).

PIPS took out more bacteria from the root canal system than traditional needle irrigation, according to Mandras et al., although the difference was not statistically significant (Mandras et al., 2020). When Arslan et al. examined the efficacy of PIPS, EndoActivator, and traditional needle irrigation in eliminating double and triple antibiotic paste, they discovered that the PIPS group outperformed the other groups statistically substantially (Arslan et al., 2014).

SWEEPS

(ShockWaveEnhancedEmissionPhotoacousticStreaming)

Whereas PIPS mode employs the emission of a single pulse of energy, SWEEPS is predicated on the delivery of shorter double pulses (25 μ s ultra short pulse) (Angerame et al., 2022). The instantaneous expansion of these cond bubble created by these cond laser pulse causes additional pressure on the first bubble, resulting in a violent burst as the shock waves are absorbed even in very narrow channels. At the same energy, the longer pulse duration is inferior to the maximum emitted power of each SWEEPS pulse is doubled by the more powerful bubble burst (Angerame et al., 2022).

During laser-activated irrigation, shock waves absorbed from these cond bursting cavitation bubbles are shaped along the entire root canal. Secondary cavitation bubbles generate shear stress and vortex flow in the root canals, removing debris, smear layer and biofilm from the root canal surface and from undetected and unshaped areas such as isthmuses, lateral canals (Jordana et al., 2022).

SWEEPS tips (400 μ) are available with straight, conical or circular terminations. This system uses a double pulse (pulses of 25 μ s duration), 0.6 W of power, using an energy level of 20 mJ at a frequency of 15 Hz. SWEEPS tips with wider (600 μ) and rounded terminations are preferred when the apical width is large SWEEPS has shown superior root canal clea-

ning following endodontic retreatment compared to PUI (Angerame et al., 2022).

GENTLEWAVE SYSTEM

In 2016, the Gentlewave (GW) (Sonendo, Laguna Hills, CA, USA) system was launched in the US (Mohammadi et al., 2017). It generates broad-spectrum sound waves and initiates multisonic sound waves, aiming to clean the root canal (Mohammadi et al., 2017).

The console and handpiece make up the system. The central unit contains three separate washing solution reservoirs, a waste bin, a degassing system and a pressure generator (Mohammadi et al., 2017). Following a final irrigation with 3% NaOCl and 8% EDTA, the root canals are washed with distilled water as part of the scheduled flushing regimen (Mohammadi et al., 2017). A wide range of sound waves are produced in the degassed solution inside the canal by the potent hydrodynamic cavitation cloud when the handpiece tip is held 1 mm above the base of the pulp chamber during the treatment (Mohammadi et al., 2017). With the least amount of instrumentation, the Gentle WaveSystem (Sonendo, Inc., Laguna Hills, CA, USA) was created to clean molar root canals. At no time during the process does the tip of the hand piece penetrate the canal. This system provides a spray distribution of irrigation solution at approximately 45 mL perminute at approximately 40 °C. The handpiece of the system provides irrigation flow to the root canal system while at the same time discharging excess fluid (Mohammadi et al., 2017). According to Haapasalo et al., the GW system dissolved tissue eight times faster than traditional irrigation and eight times faster than ultrasonic devices (Haapasalo et al., 2014). Wright et al. investigated the effectiveness of GW, EndoVac and CNI with a side-vented needle in root canal retreatment. The study found that although EndoVac group eliminated less gutta percha than GW and traditional irrigation, this difference was not statistically important (Erratum et al 2019). According to Chan et al., GW irrigation was very successful in clearing away debris that had collected in the mandibular molars' mesial root isthmuses (Chan et al., 2019). GW irrigation was superior to conventional irrigation, but statistically similar to continuous ultrasonic irrigation (Chan et al., 2019). Debris tereduction rates were found to be 96.4% and 97.9% for canals and isthmuses in GW irrigation, respectively, while 91.2% and 93.5% reduction was observed for continuous ultrasonic irrigation (Chan et al., 2019).

References

- Ahmad, M., Pitt Ford, T. R., & Crum, L. A. (1987). Ultrasonic debridement of root canals: An insight into the mechanisms involved. *Journal of Endodontics*, 13(3). [https://doi.org/10.1016/S0099-2399\(87\)80173-5](https://doi.org/10.1016/S0099-2399(87)80173-5)
- Akçay, M., Arslan, H., Durmus, N., Mese, M., & Capar, I. D. (2016). Dentinal tubule penetration of AH Plus, iRoot SP, MTA fillapex, and guttaflow bio-seal root canal sealers after different final irrigation procedures: A confocal microscopic study. *Lasers in Surgery and Medicine*, 48(1). <https://doi.org/10.1002/lsm.22446>
- Akyüz Ekim, Ş. N., & Erdemir, A. (2015). Endodontide İrrigasyon Aktivasyon Yöntemleri. *Atatürk Üniversitesi Diş Hekimliği Fakültesi Dergisi*, 10(10). <https://doi.org/10.17567/dfd.29335>
- Al-Hadlaq, S. M., Al-Turaiki, S. A., Al-Sulami, U., & Saad, A. Y. (2006). Efficacy of a New Brush-Covered Irrigation Needle in Removing Root Canal Debris: A Scanning Electron Microscopic Study. *Journal of Endodontics*, 32(12). <https://doi.org/10.1016/j.joen.2006.07.019>
- Angerame, D., De Biasi, M., Porrelli, D., Bevilacqua, L., Zanin, R., Olivi, M., Kaitsas, V., & Olivi, G. (2022). Retreatability of calcium silicate-based root canal sealer using reciprocating instrumentation with different irrigation activation techniques in single-rooted canals. *Australian Endodontic Journal*, 48(3). <https://doi.org/10.1111/aej.12603>
- Arslan, H., Akçay, M., Capar, I. D., Ertas, H., Ok, E., & Uysal, B. (2014). Efficacy of needle irrigation, EndoActivator, and photon-initiated photoacoustic streaming technique on removal of double and triple antibiotic pastes. *Journal of Endodontics*, 40(9). <https://doi.org/10.1016/j.joen.2014.02.013>
- Bao, P., Shen, Y., Lin, J., & Haapasalo, M. (2017). In Vitro Efficacy of XP-endo Finisher with 2 Different Protocols on Biofilm Removal from Apical Root Canals. *Journal of Endodontics*, 43(2). <https://doi.org/10.1016/j.joen.2016.09.021>
- Basrani, B., Tjäderhane, L., Santos, J. M., Pascon, E., Grad, H., Lawrence, H. P., & Friedman, S. (2003). Efficacy of chlorhexidine- and calcium hydroxide-containing medicaments against *Enterococcus faecalis* in vitro. *Oral Surgery, Oral Medicine, Oral Pathology, Oral Radiology, and Endodontics*, 96(5). [https://doi.org/10.1016/S1079-2104\(03\)00166-5](https://doi.org/10.1016/S1079-2104(03)00166-5)
- Beer, F., Buchmair, A., Wernisch, J., Georgopoulos, A., & Moritz, A. (2012). Comparison of two diode lasers on bactericidity in root canals-an in vitro study. *Lasers in Medical Science*, 27(2). <https://doi.org/10.1007/s10103-011-0884-3>
- Çakıcı, F., Çakıcı, E. B., Sadık, B., Keleş, A., & Küçükkekenci, F. F. (2019). Comparison of newly formed microcracks after instrumentation using Protaper

Next, Reciproc and Self-Adjusting File systems. *European Oral Research*, 53(1). <https://doi.org/10.26650/eor.201972917418>

Canavar T, Eren İ, & Bayram M. (2020). Endodontide İrrigasyon Solüsyonu Olarak Kullanılan Bitkisel Alternatifler. *Dent & Med J - R*, 23, 156–173.

Caron, G. (2007). Cleaning efficiency of the apical millimeters of curved canals using three different modalities of irrigant activation: an SEM study. *Paris: Paris VII University*.

Chan, R., Versiani, M. A., Friedman, S., Malkhassian, G., Sousa-Neto, M. D., Leoni, G. B., Silva- Sousa, Y. T. C., & Basrani, B. (2019). Efficacy of 3 Supplementary Irrigation Protocols in the Removal of Hard Tissue Debris from the Mesial Root Canal System of Mandibular Molars. *Journal of Endodontics*, 45(7). <https://doi.org/10.1016/j.joen.2019.03.013>

Conde, A. J., Estevez, R., Loroño, G., Valencia de Pablo, Rossi-Fedele, G., & Cisneros, R. (2017). Effect of sonic and ultrasonic activation on organic tissue dissolution from simulated grooves in root canals using sodium hypochlorite and EDTA. *International Endodontic Journal*,

50(10). <https://doi.org/10.1111/iej.12717>

de Gregorio, C., Estevez, R., Cisneros, R., Heilborn, C., & Cohenca, N. (2009). Effect of EDTA, Sonic, and Ultrasonic Activation on the Penetration of Sodium Hypochlorite into Simulated Lateral Canals: An In Vitro Study. *Journal of Endodontics*, 35(6). <https://doi.org/10.1016/j.joen.2009.03.015>

De-Deus, G., Souza, E. M., Barino, B., Maia, J., Zamolyi, R. Q., Reis, C., & Kfir, A. (2011). The self-adjusting file optimizes debridement quality in oval-shaped root canals. *Journal of Endodontics*, 37(5). <https://doi.org/10.1016/j.joen.2011.02.001>

Desai, P., & Himel, V. (2009). Comparative Safety of Various Intracanal Irrigation Systems.

Journal of Endodontics, 35(4). <https://doi.org/10.1016/j.joen.2009.01.011>

Donnermeyer, D., Wyrsh, H., Bürklein, S., & Schäfer, E. (2019). Removal of Calcium Hydroxide from Artificial Grooves in Straight Root Canals: Sonic Activation Using EDDY Versus Passive Ultrasonic Irrigation and XPen-do Finisher. *Journal of Endodontics*, 45(3). <https://doi.org/10.1016/j.joen.2018.11.001>

Dornelles-Morgental, R., Guerreiro-Tanomaru, J. M., De Faria-Jnior, N. B., Hungaro-Duarte, M. A., Kuga, M. C., & Tanomaru-Filho, M. (2011). Antibacterial efficacy of endodontic irrigating solutions and their combinations in root canals contaminated with *Enterococcus faecalis*. *Oral Surgery, Oral Medicine, Oral Pathology, Oral Radiology and Endodontology*,

112(3). <https://doi.org/10.1016/j.tripleo.2011.02.004>

Dunavant, T. R., Regan, J. D., Glickman, G. N., Solomon, E. S., & Honeyman, A. L. (2006). Comparative Evaluation of Endodontic Irrigants against Ente-

- rococcus faecalis Biofilms. *Journal of Endodontics*, 32(6). <https://doi.org/10.1016/j.joen.2005.09.001>
- El Ashiry, E. A., & Farsi, N. M. (2018). Prevalence of extra root canal orifices of maxillary first permanent molars in a Saudi subpopulation utilizing micro-computed tomography. *Journal of Contemporary Dental Practice*, 19(11). <https://doi.org/10.5005/jp-journals-10024-2424>
- Erratum: Effectiveness of Gutta-percha/Sealer Removal during Retreatment of Extracted Human Molars Using the GentleWave System (Journal of Endodontics (2019) 45(6) (808–812), (S0099239919301189), (10.1016/j.joen.2019.02.009)). (2019). In *Journal of Endodontics* (Vol. 45, Issue 8). <https://doi.org/10.1016/j.joen.2019.05.019>
- Gao, Y., Haapasalo, M., Shen, Y., Wu, H., Li, B., Ruse, N. D., & Zhou, X. (2009). Development and Validation of a Three-dimensional Computational Fluid Dynamics Model of Root Canal Irrigation. *Journal of Endodontics*, 35(9). <https://doi.org/10.1016/j.joen.2009.06.018>
- Gu, L. sha, Kim, J. R., Ling, J., Choi, K. K., Pashley, D. H., & Tay, F. R. (2009). Review of Contemporary Irrigant Agitation Techniques and Devices. In *Journal of Endodontics* (Vol. 35, Issue 6). <https://doi.org/10.1016/j.joen.2009.03.010>
- Gündoğar, M., Sezgin, G. P., Kaplan, S. S., Özyürek, H., Uslu, G., & Özyürek, T. (2021).
Postoperative pain after different irrigation activation techniques: a randomized, clinical trial.
Odontology, 109(2). <https://doi.org/10.1007/s10266-020-00553-5>
- Haapasalo, M., Shen, Y., Qian, W., & Gao, Y. (2010). Irrigation in Endodontics. In *Dental Clinics of North America* (Vol. 54, Issue 2). <https://doi.org/10.1016/j.cden.2009.12.001>
- Haapasalo, M., Wang, Z., Shen, Y., Curtis, A., Patel, P., & Khakpour, M. (2014). Tissue dissolution by a novel Multisonic Ultracleaning system and sodium hypochlorite. *Journal of Endodontics*, 40(8). <https://doi.org/10.1016/j.joen.2013.12.029>
- Hauser, V., Braun, A., & Frentzen, M. (2007). Penetration depth of a dye marker into dentine using a novel hydrodynamic system (RinsEndo®). *International Endodontic Journal*, 40(8). <https://doi.org/10.1111/j.1365-2591.2007.01264.x>
- İnce Yusufoglu, S., Keskin, N. B., Saricam, E., & Bozkurt, D. A. (2020). Comparison of apical debris extrusion using EDDY, passive ultrasonic activation and photon-initiated photoacoustic streaming irrigation activation devices. *Australian Endodontic Journal*, 46(3). <https://doi.org/10.1111/aej.12429>
- Jordana, J., Nicholas Tandean, J., Fiona Salim, J., Cahyani, F., & Sampoerno, G. (2022). Shock wave enhanced emission photoacoustic streaming (SWE-EPS): An alternative to conventional irrigation in endodontic treatment.

Conservative Dentistry Journal, 12(2). <https://doi.org/10.20473/cdj.v12i2.2022.68-72>

- Karade, P., Johnson, A., Baeten, J., Chopade, R., & Hoshing, U. (2018). Smear Layer Removal Efficacy Using EndoActivator and EndoUltra Activation Systems: An Ex Vivo SEM Analysis. *Compendium of Continuing Education in Dentistry (Jamesburg, N.J. : 1995)*, 39(4).
- Keir, D. M., Senia, E. S., & Montgomery, S. (1990). Effectiveness of a brush in removing postinstrumentation canal debris. *Journal of Endodontics*, 16(7). [https://doi.org/10.1016/S0099-2399\(06\)81942-4](https://doi.org/10.1016/S0099-2399(06)81942-4)
- Langeland, K., Liao, K. (King S., & Pascon, E. A. (1985). Work-saving devices in endodontics: Efficacy of sonic and ultrasonic techniques. *Journal of Endodontics*, 11(11). [https://doi.org/10.1016/S0099-2399\(85\)80223-5](https://doi.org/10.1016/S0099-2399(85)80223-5)
- Mandras, N., Pasqualini, D., Roana, J., Tullio, V., Banche, G., Gianello, E., Bonino, F., Cuffini, A. M., Berutti, E., & Alovise, M. (2020). Influence of photon-induced photoacoustic streaming (Pips) on root canal disinfection and post-operative pain: A randomized clinical trial. *Journal of Clinical Medicine*, 9(12). <https://doi.org/10.3390/jcm9123915>
- Meltem Küçük, Fatma Kermeoğlu, & Atakan Kalender. (2016). Endodontide Kullanılan Güncel İrrigasyon Solüsyonları, Sistem ve Cihazları. İnönü Üniversitesi Sağlık Bilimleri Dergisi, 5(1), 29–37.
- Merino, A., Estevez, R., de Gregorio, C., & Cohenca, N. (2013). The effect of different taper preparations on the ability of sonic and passive ultrasonic irrigation to reach the working length in curved canals. *International Endodontic Journal*, 46(5). <https://doi.org/10.1111/iej.12006>
- Metzger, Z. (2014). The self-adjusting file (SAF) system: An evidence-based update. *Journal of Conservative Dentistry*, 17(5), 401. <https://doi.org/10.4103/0972-0707.139820>
- Mohammadi, Z., Jafarzadeh, H., Shalavi, S., & Palazzi, F. (2017). Recent advances in root canal disinfection: A review. In *Iranian Endodontic Journal* (Vol. 12, Issue 4). <https://doi.org/10.22037/iej.v12i4.17935>
- Mohammadi, Z., Shalavi, S., Kinoshita, J. I., Giardino, L., Gutmann, J. L., Banihashem Rad, S. A., Udoe, C. I., & Jafarzadeh, H. (2021). A Review on Root Canal Irrigation Solutions in Endodontics. In *Journal of Dental Materials and Techniques* (Vol. 10, Issue 3). <https://doi.org/10.22038/JDMT.2021.56003.1431>
- Önay EO, Kurt E, Kızılırmak İ, Nuyan D, Güran Ç, & Erdoğan T. (2013). Kök Kanal İrrigasyonunda Geleneksel ve Güncel Yaklaşımlar. *ADO Klinik Bilimler Dergisi*, 7(2), 1459–1468.
- Pesse, A. V., Warriar, G. R., & Dhir, V. K. (2005a). An experimental study of the gas entrapment process in closed-end microchannels. *International Jour-*

- nal of Heat and Mass Transfer*, 48(25– 26). <https://doi.org/10.1016/j.ijheatmasstransfer.2005.07.020>
- Pesse, A. V., Warriar, G. R., & Dhir, V. K. (2005b). An experimental study of the gas entrapment process in closed-end microchannels. *International Journal of Heat and Mass Transfer*, 48(25– 26), 5150–5165. <https://doi.org/10.1016/j.ijheatmasstransfer.2005.07.020>
- Peters, O. A., Bardsley, S., Fong, J., Pandher, G., & Divito, E. (2011). Disinfection of root canals with photon-initiated photoacoustic streaming. *Journal of Endodontics*, 37(7). <https://doi.org/10.1016/j.joen.2011.03.016>
- Peters, O. A., Schönenberger, K., & Laib, A. (2001). Effects of four Ni-Ti preparation techniques on root canal geometry assessed by micro computed tomography. *International Endodontic Journal*, 34(3). <https://doi.org/10.1046/j.1365-2591.2001.00373.x>
- Ram, Z. (1977). Effectiveness of root canal irrigation. *Oral Surgery, Oral Medicine, Oral Pathology*, 44(2). [https://doi.org/10.1016/0030-4220\(77\)90285-7](https://doi.org/10.1016/0030-4220(77)90285-7)
- Rödig, T., Bozkurt, M., Konietschke, F., & Hülsmann, M. (2010). Comparison of the vibringe system with syringe and passive ultrasonic irrigation in removing debris from simulated root canal irregularities. *Journal of Endodontics*, 36(8). <https://doi.org/10.1016/j.joen.2010.04.023>
- Salas, H., Castrejon, A., Fuentes, D., Luque, A., & Luque, E. (2021). Evaluation of the penetration of CHX 2% on dentinal tubules using Conventional Irrigation, Sonic Irrigation (EDDY) and Passive Ultrasonic Irrigation (PUI) techniques: An in vitro study. *Journal of Clinical and Experimental Dentistry*, 13(1). <https://doi.org/10.4317/JCED.57065>
- Sarno, M. U., Sidow, S. J., Looney, S. W., Lindsey, K. W., Niu, L. N., & Tay, F. R. (2012). Canal and isthmus debridement efficacy of the VPro endosafe negative-pressure irrigation technique. *Journal of Endodontics*, 38(12). <https://doi.org/10.1016/j.joen.2012.09.002>
- Schoop, U., Kluger, W., Dervisbegovic, S., Goharkhay, K., Wernisch, J., Georgopoulos, A., Sperr, W., & Moritz, A. (2006). Innovative wavelengths in endodontic treatment. *Lasers in Surgery and Medicine*, 38(6). <https://doi.org/10.1002/lsm.20331>
- Sedgley, C., Applegate, B., Nagel, A., & Hall, D. (2004). Real-time imaging and quantification of bioluminescent bacteria in root canals in vitro. *Journal of Endodontics*, 30(12). <https://doi.org/10.1097/01.DON.0000132299.02265.6C>
- Setlock, J., Fayad, M. I., BeGole, E., & Bruzick, M. (2003). Evaluation of canal cleanliness and smear layer removal after the use of the Quantec-E irrigation system and syringe: A comparative scanning electron microscope study. *Oral Surgery, Oral Medicine, Oral Pathology, Oral Radiology, and Endodontics*, 96(5). [https://doi.org/10.1016/S1079-2104\(03\)00302-0](https://doi.org/10.1016/S1079-2104(03)00302-0)
- Thulaseedharan, S., Kabbinala, P., Vallabhdas, A. K., Gowda, V. K. C. N., Chandrashekar, K. S., & Marulappa, R. (2020). In vitro comparative evaluation of

- effectiveness of sodium hypochlorite with conventional irrigation method versus EndoVac and ultrasonic irrigation in the elimination of *Enterococcus faecalis* from root canals. *Journal of Pharmacy and Bioallied Sciences*, 12(5). https://doi.org/10.4103/jpbs.JPBS_37_20
- Toljan, I., Bago Jurič, I., & Anić, I. (2016). Eradication of Intracanal *Enterococcus Faecalis* Biofilm by Passive Ultrasonic Irrigation and RinsEndo System. *Acta Stomatologica Croatica*, 50(1). <https://doi.org/10.15644/asc50/1/3>
- Tomson, P. L., & Simon, S. R. (2016). Contemporary Cleaning and Shaping of the Root Canal System. In *Primary dental journal* (Vol. 5, Issue 2). <https://doi.org/10.1308/205016816819304196>
- Urban, K., Donnermeyer, D., Schäfer, E., & Bürklein, S. (2017). Canal cleanliness using different irrigation activation systems: a SEM evaluation. *Clinical Oral Investigations*, 21(9). <https://doi.org/10.1007/s00784-017-2070-x>
- Van Der Sluis, L. W. M., Gambarini, G., Wu, M. K., & Wesselink, P. R. (2006). The influence of volume, type of irrigant and flushing method on removing artificially placed dentine debris from the apical root canal during passive ultrasonic irrigation. *International Endodontic Journal*, 39(6). <https://doi.org/10.1111/j.1365-2591.2006.01108.x>
- Van Der Sluis, L. W. M., Versluis, M., Wu, M. K., & Wesselink, P. R. (2007). Passive ultrasonic irrigation of the root canal: A review of the literature. In *International Endodontic Journal* (Vol. 40, Issue 6). <https://doi.org/10.1111/j.1365-2591.2007.01243.x>
- Vineet, A. S., Rajesh, M., Sonali, & Mukesh. (2014). A Contemporary Overview of Endodontic Irrigants – A Review. *J Dent App . J Dent App*, 1(1).
- Vivan, R. R., Bortolo, M. V., Antonio, M., Duarte, H., & Tanomaru-filho, M. (2010). Vivan et al. SEM analysis of RinsEndo System and Conventional Irrigation for Debris Removal. *Braz Dent J* 2010 Vol 21 No 4. *Brazilian Dental Journal*, 21.
- Walmsley, A. D., & Williams, A. R. (1989). Effects of constraint on the oscillatory pattern of endosonic files. *Journal of Endodontics*, 15(5). [https://doi.org/10.1016/S0099-2399\(89\)80233-X](https://doi.org/10.1016/S0099-2399(89)80233-X)
- Walters, M. J., Baumgartner, J. C., & Marshall, J. G. (2002). Efficacy of irrigation with rotary instrumentation. *Journal of Endodontics*, 28(12). <https://doi.org/10.1097/00004770-200212000-00011>
- Weller, R. N., Brady, J. M., & Bernier, W. E. (1980). Efficacy of ultrasonic cleaning. *Journal of Endodontics*, 6(9). [https://doi.org/10.1016/S0099-2399\(80\)80185-3](https://doi.org/10.1016/S0099-2399(80)80185-3)
- Yilmaz, M., Yilmaz, S., Dumani, A., Kuden, C., & Yoldas, O. (2017). Effects of seven different irrigation techniques on debris and the smear layer: A scan-

ning electron microscopy study. *Nigerian Journal of Clinical Practice*, 20(3). <https://doi.org/10.4103/1119-3077.180061>

Zmener, O., Pameijer, C. H., Serrano, S. A., Palo, R. M., & Iglesias, E. F. (2009). Efficacy of the NaviTip FX Irrigation Needle in Removing Post Instrumentation Canal Smear Layer and Debris in Curved Root Canals. *Journal of Endodontics*, 35(9). <https://doi.org/10.1016/j.joen.2009.05>

CHAPTER 4

THE EFFECT OF BARRIER MATERIALS USED IN REGENERATIVE ENDODONTIC TREATMENT ON DISCOLORATION AND TREATMENT METHODS

Şebnem DURUKAN¹

Özgün GÜLDEREN²

Esmâ SARIÇAM³

1 Research Assistant Ankara Yıldırım Beyazıt University Faculty of Dentistry 0009-0000-6971-435X

2 Speacialist Dentist Ankara Yıldırım Beyazıt University Faculty of Dentistry 0009-0003-8929-8965

3 Associate Professor Ankara Yıldırım Beyazıt University Faculty of Dentistry 0000-0001-7701-4214

1.)THE NEED FOR ENDODONTIC TREATMENT IN IMMATURE PERMANENT TEETH

Pulp necrosis may develop in immature permanent teeth with open apices due to dental anomalies such as caries, trauma, dens evaginatus, and dens invaginatus (Dahl and Pallesen, 2003). Various factors such as the extent of damage, the type of fracture if present, whether the tooth is necrotic, the presence of infection, the condition of surrounding periodontal tissues, the presence of periapical lesions, the stage of development the tooth is in, vitality, and the patient's age and health are determining factors in the treatment options for the tooth (Frank and Alfred, 1966).

Following the evaluation of the pulp, a decision must be made between apexogenesis, apexification, the apical plug method and RET (regenerative endodontic treatment). These treatments are important as they ensure the continued development of the root canal, reduce the risk of future root fractures, and contribute to the crown/root ratio of the treated tooth (Flanagan and Andrew, 2014).

1.1.)Apexification

Apexification is an alternative root canal treatment procedure based on creating an artificial or natural apical barrier by closing the apex with a mineralized plug to prevent apical leakage in necrotic immature teeth (Ford, 1996). The traditional apexification method (also known as the Frank method) involves the use of $\text{Ca}(\text{OH})_2$, which promotes the completion of root development and apical closure, allowing permanent root canal treatment to follow (Abbott and Paul, 1998; Jeeruphan et al., 2012; Thäter and Marechoux, 1988). There are several disadvantages to $\text{Ca}(\text{OH})_2$ apexification. These include the long time required for the completion of the entire treatment, multiple sessions that inevitably incur clinical costs for patients, and the increased risk of tooth fracture when $\text{Ca}(\text{OH})_2$ is used as a long-term root canal dressing (Cvek and Miomir, 1992). These disadvantages have led to the use of mineral trioxide aggregate (MTA) to achieve apical sealing without the need for calcific barrier formation.

1.2.)Apical Plug Method

MTA apexification, a clinical technique aimed at creating an apical barrier in a single visit, has been introduced to overcome the disadvantages of calcium hydroxide apexification (Cvek and Miomir, 1992; Frank and Alfred, 1966). Although apexification treatments with calcium hydroxide and MTA have similar clinical and radiographic success rates and apical barrier formation rates, MTA is associated with a significantly shorter time

for apical barrier formation. This has made a difference in the overall success rate, considering the many failures encountered with calcium hydroxide (Lin et al., 2016). Additionally, MTA has been reported to form an apical hard tissue barrier and lamina dura more quickly than calcium hydroxide in radiographs (Lin et al., 2016). Other studies comparing MTA with calcium hydroxide have shown that it also reduces the likelihood of long-term tooth fractures (Bonte et al., 2015; Torabinejad et al., 2018).

1.3.)Regenerative Endodontic Treatment (RET)

Regenerative endodontics is defined as “biologically based procedures designed to replace damaged tooth structures, including dentin and root structures as well as cells of the pulp-dentin complex.” Based on this definition, RET aims to repair the damaged pulp-dentin complex in immature permanent teeth with necrotic pulp due to infection, trauma, or other causes (Murray et al., 2007).

The RET protocol recommended by AAE;

In the first visit, local anesthesia is applied, the tooth is isolated with a rubber dam, and the endodontic access cavity is opened. The root canal system is then irrigated with minimal or no instrumentation using irrigation solutions (20 ml of 1.5% sodium hypochlorite per canal, followed by 20 ml of sterile saline per canal). Afterward, the root canals are dried, and medicaments (such as antibiotic pastes or calcium hydroxide) are applied. Due to the discoloration caused by minocycline in the triple antibiotic paste, a double antibiotic paste may also be preferred as a root canal disinfectant.

In the second visit, if signs of inflammation persist, medicament is reapplied to the root canal. Once inflammation is under control, anesthesia with 3% mepivacaine without vasoconstrictor is administered, and isolation with a rubber dam is maintained. For irrigation, 20 ml of 17% ethylenediaminetetraacetic acid (EDTA) is applied, followed by drying of the canal. Pre-bent sterile K-type files are then rotated 2 mm beyond the apex to induce bleeding into the canal. The blood should reach the cemento-enamel junction. Bleeding in the coronal third of the root is then halted, and the area is covered with MTA (or alternatively Biodentine). The MTA is covered with a base material, and the treatment is completed with the restoration of the crown (Barao Var et al., 2016).

1.3.1.)Advantages of Regenerative Endodontic Treatment (RET)

RET is a relatively simple treatment method to apply in a clinical setting. It is a cost-effective biotechnological treatment protocol using routine hand tools and medicaments (Murray et al., 2007). The greatest advantage

of RET is that it promotes root development and hard tissue accumulation by effectively thickening the dentin walls. Depending on the stage of root development, the risk of cervical root fractures after treatment decreases by 28% to 77% (Poly A et al., 2019; Shokouhinejad et al., 2019). This treatment generally does not involve complications such as rejection by the immune system or the transfer of external pathogens (Parolia et al., 2010).

In recent years, many studies have reported that RET can lead to the formation of new roots even in immature permanent teeth with periapical abscesses and periradicular bone resorption. Root formation has also been observed in teeth with lesions and sinus tracts caused by pulp necrosis (Petrino et al., 2010; Wang et al., 2010). According to the American Association of Endodontists (AAE) and the European Society of Endodontology (ESE), the RET protocol generally requires at least two visits (AAE, 2016; ESE, 2016). In most published case reports and series of RET in necrotic pulped immature teeth, calcium hydroxide or triple antibiotic paste has been used as an intracanal medicament over multiple visits (Diogenes et al., 2013). However, some RET case reports have shown successful outcomes even with a single-visit treatment without any intracanal medicament (Chaniotis, 2016; McCabe, 2015; Shin et al., 2009; Topcuoglu, 2016).

1.3.2.)Disadvantages of Regenerative Endodontic Treatment

Along with its advantages, RET has some disadvantages, including the potential for resistant bacterial strains to develop and the possibility of allergic reactions (Thibodeau et al., 2007). The patient's existing systemic disease or immunological problems can reduce the chances of treatment success. One of the most significant disadvantages is the inability to fully determine the density and composition of the cells within the blood clot, which serves as a scaffold during treatment (Thibodeau et al., 2007). It is also uncertain whether root canal obliteration or apical periodontitis will develop in the long term after treatment (Banchs and Trope, 2004).

2.)DISCOLORATION OF TEETH

One of the key goals of modern aesthetic dentistry is to maintain the natural color of teeth while meeting the patient's aesthetic expectations (Pizzamiglio, 1991). Therefore, any conditions that compromise the natural color of the teeth after treatment are considered a sign of aesthetic failure.

Light with wavelengths between 400-700 nm can be perceived by the human eye. The concept of color arises when light reaches and is interpreted by the retina (Chu et al., 2004; Doğan and Yüzügüllü, 2011). The

natural color of teeth is white, which is the result of a blend of various wavelengths of light. Each person's natural tooth color is unique and influenced by several factors (Dayan et al., 1983). One such factor is aging, where the enamel layer thins, causing more of the underlying dentin to reflect through, making the tooth appear more yellow (Dayan et al., 1983; Gurel, 2004). While this is a natural process, other non-natural causes of tooth discoloration can develop, negatively impacting the aesthetic appearance of a patient's smile (Joiner and Andrew, 2004).

Tooth discoloration varies based on etiology, appearance, location, severity, and affinity to tooth structure (Dahl and Pallesen, 2003). It can be classified as intrinsic, extrinsic, or a combination of both, depending on its origin and cause (Hattab et al., 1999).

2.1.)Intrinsic Discoloration

Intrinsic discoloration occurs due to changes in the structural composition or thickness of the tooth's hard tissues (both enamel and dentin). This means that chromogenic material becomes incorporated into the tooth's hard tissue. Such discoloration may occur due to developmental issues like fluorosis or tetracycline staining during tooth development (pre-eruption), or it can occur post-eruption due to pulp necrosis. These discolorations can also be localized to one or a few teeth due to trauma, inadequate or incorrect endodontic treatment, or restorations (such as amalgam) (Alazmah, 2021).

2.2.)Extrinsic Discoloration

Extrinsic discoloration occurs on the outer surface of the tooth or within the pellicle layer that forms over the tooth. In milk teeth and immature permanent teeth, poor oral hygiene, the use of iron supplements, and the presence of chromogenic bacteria are common causes of extrinsic staining (Watts and Addy, 2001; Saba et al., 2006).

3.)TOOTH DISCOLORATION FOLLOWING ENDODONTIC TREATMENT

Discolorations occurring after endodontic treatment can be attributed to excessive bleeding during the removal of the pulp or the presence of residual pulp tissue. Endodontic medicaments containing barium, iodine, or silver, as well as gutta-percha and root canal sealers, can also cause discoloration in teeth (Bizhang et al., 2003).

Discoloration resulting from the use of endodontic medicaments or root canal sealers can appear orange-red, dark red, gray, or black. Several laboratory studies have shown that zinc oxide eugenol and epoxy resin-based root canal sealers can cause moderate to severe color changes (Bizhang et al., 2003; Ioannidis et al., 2013).

Just as discolorations can develop due to the materials used in endodontic treatments, discolorations can also occur due to the materials used in regenerative endodontic treatment (RET). It is known that minocycline, found in the triple antibiotic paste used for disinfection during RET, leads to discoloration of the teeth. Calcium hydroxide, used as an intracanal medicament in RET, can also cause discoloration (Kahler et al., 2016). MTA, frequently used in RET due to its biocompatibility, can also lead to discoloration in teeth and adjacent soft tissues (Belobrov et al., 2011). Discoloration has been observed in both gray and white formulations. Felman and Parashos reported that the presence of bleeding in the environment along with MTA would increase discoloration, although the mechanism behind this effect is still not fully understood (Felman et al., 2013). Additionally, the presence of heavy metal ions and bismuth oxide, a radiopaque component of MTA, is also thought to contribute to color changes (Belobrov et al., 2011). Similarly, discoloration has been observed in 60% of cases treated with MTA for pulpotomy (Naik and Hegde, 2005).

4.)DISCOLORATIONS ASSOCIATED WITH MATERIALS USED IN REGENERATIVE ENDODONTIC TREATMENT (RET)

Comprehensive studies in the literature have indicated that materials used in RET have the potential to cause visible tooth discolorations that can significantly and negatively affect the quality of life in children. Patients, especially those with anterior teeth, desire both successful treatment and aesthetic results; therefore, materials and procedures with the lowest possible discoloration potential should be carefully selected (Kahler and Rossi-Fedele, 2016).

When evaluating discoloration resulting from RET, the primary materials that come to mind include the solutions used, intracanal medicaments, coronal barrier materials, and bleeding that serves as a scaffold within the canal.

Considering the effect of materials used in root canal treatment on discoloration, the solutions that are particularly noteworthy include sodium hypochlorite, which is used only in the initial stage due to its toxic effects on stem cells and is generally thought not to cause discoloration. However, some studies have shown that it can lead to a deterioration of dentin color.

This color change is thought to result from contact with erythrocytes and crystallization within the root dentin (Gutiérrez et al., 1968).

The most recent guidelines suggested by the American Association of Endodontists (AAE) indicate that calcium hydroxide, triple antibiotic paste (TAP), and double antibiotic paste (DAP) can all be used for root canal disinfection (Akbulut et al., 2017). In a position statement published in 2016 by the European Society of Endodontology (ESE) regarding RET, it was emphasized that there is no strong evidence supporting the use of antibiotics during regenerative treatments; instead, calcium hydroxide was recommended (Galler, 2016).

In a study on the discoloration caused by different endodontic materials, it was determined that the triple antibiotic paste caused the most severe discoloration, attributed to minocycline contained in the paste (Kim et al., 2010; Nosrat et al., 2013). The discoloration resulting from the application of minocycline-containing antibiotic combinations is generally severe. Some studies suggest that using calcium hydroxide as an intracanal medicament can completely prevent this discoloration (Cehreli et al., 2011; Nagata et al., 2014). However, there are also studies reporting that discoloration occurred after RET using calcium hydroxide (Iwaya et al., 2001).

A detailed examination of the literature shows that while many studies indicate that minocycline in triple antibiotic paste causes discoloration (Akçay et al., 2013; Almeida et al., 2020), there are also studies concluding that the triple antibiotic paste itself causes discoloration (Santos et al., 2017). In a study by Kucukekenci and colleagues investigating the effects of modified triple antibiotic pastes, it was found that antibiotic pastes containing amoxicillin, cefaclor, and doxycycline caused discoloration without significant differences between them, while the group containing minocycline showed greater discoloration in line with other studies (Kucukekenci et al., 2019). Another study by Kohli and colleagues found greater discoloration in groups treated with white MTA and triple antibiotic paste containing minocycline (Kohli et al., 2015).

It is known that MTA, which is biocompatible and used as a coronal barrier material in RET, can also lead to discoloration in teeth (Belobrov et al., 2011). MTA is a mixture of tricalcium silicate, dicalcium silicate, tricalcium aluminate, tetracalcium aluminoferrite, and bismuth oxide (Camilleri, 2015; Sarkar et al., 2005). This mixture provides high biocompatibility and low cytotoxicity (Torabinejad et al., 1994; Torabinejad and Parirokh, 2010). Despite its beneficial properties, one of the significant disadvantages of MTA, when used as a coronal barrier, is the color change of crowns in anterior teeth (Felman and Parashos, 2013; Jang et al., 2013; Kang, 2015; Karabucak et al., 2005; Marciano et al., 2014). This issue le-

ads to patient dissatisfaction rates ranging from 31.6% to 57% (Arman et al., 2015). A recent study by Mishra and colleagues found that discoloration was observed in all groups, including gray and white MTA, Biodentine, and white MTA developed to reduce the discoloration effect of gray MTA; the least discoloration was seen in the Biodentine group, while the greatest was in the gray MTA group (Mishra et al., 2024).

In another study investigating the effect of ultrasonic activation on discoloration, MTA Angelus, MTA Repair HP, and Biodentine were used as coronal barrier materials. Discoloration was observed only in MTA groups that were not activated ultrasonically (Aguiar et al., 2019).

In other studies, researchers examined groups containing medications, coronal materials, and blood together, finding that groups using triple antibiotic paste containing blood and minocycline had more discoloration (Dettwiler et al., 2016; Felman and Parashos, 2013; Lenherr et al., 2012).

In a study conducted by Palma and colleagues on acrylic teeth, MTA and Biodentine were selected as coronal barrier materials, and the teeth were divided into two subgroups based on whether saline or blood was used. Six months after the color measurements, the MTA/saline group caused more color change than the Biodentine/saline group, while the MTA/blood group led to more discoloration than the Biodentine/blood group (Palma et al., 2019).

In another study using MTA Flow, UltraCal XS, and BioC Temp, it was found that all materials showed more discoloration than expected; the Bio-C Temp barrier material caused less or similar discoloration compared to MTA Flow and UltraCal XS (Oliveira et al., 2020).

Shokouhinejad and colleagues conducted many studies on the effect of materials used in RET on discoloration. In a study using saline and blood, it was concluded that the most discoloration occurred when Ortho MTA was used with blood (Shokouhinejad et al., 2015). In studies comparing PRF and blood, it was found that the group using blood showed more discoloration after one month (Shokouhinejad et al., 2019). In a study where OrthoMTA, RetroMTA, and TotalFill-BC-RRM were used as barrier materials, blood, PRF, and PBS were used as scaffolds. The groups that used blood showed more discoloration than those that used PRF and PBS, while OrthoMTA groups exhibited more discoloration compared to RetroMTA and TotalFill groups (Shokouhinejad et al., 2023).

In innovative studies where various methods have been attempted to prevent discoloration, Shokouhinejad and colleagues used different coronal materials and covered the cavity with a dentin bonding agent in one

group, while the other group did not; they found that the covered walls showed less discoloration (Shokouhinejad et al., 2018).

In another study using Biodentine, OrthoMTA, and MTA Repair HP as barrier materials, blood and platelet-rich fibrin (PRF) were used as scaffolds, and the group using PRF and MTA Repair HP exhibited the least discoloration (Fagogeni et al., 2022).

In another study comparing scaffolds, both blood and PRF were used, with the blood groups showing more discoloration than the PRF groups (Altun and Turkyilmaz, 2024). In a study measuring color change over one year using Biodentine, MTA Angelus, BioAggregate, and only blood, the most discoloration was observed in the group using only blood, followed by BioAggregate, MTA Angelus, and finally Biodentine (Yoldas et al., 2016).

A detailed review of the literature indicates that while various factors can cause tooth discoloration, the primary reasons for discoloration associated with RET include the minocycline found in the triple antibiotic paste used for canal disinfection, interactions of irrigation solutions with dentin and each other, the use of MTA as an intracanal barrier, and the formation of clots within the canal.

5.)STRATEGIES FOR MANAGING DISCOLORATION RELATED TO REGENERATIVE ENDODONTIC TREATMENT

Full ceramic crown restorations are one of the frequently preferred treatment options for congenital or acquired tooth discolorations (Korkmaz, 2014; Rosenstiel et al., 2022). Laminate veneers are also considered as a treatment option for discolorations affecting one or more teeth that may be classified as severe. These restorations can be prepared directly or indirectly using porcelain or composite materials (Heymann and Ritter, 2018; Hobo and Iwata, 1985; Peumans et al., 2000). Tooth whitening treatment, which is a more conservative approach compared to laminate veneers and crown restorations, is another commonly used treatment option for discolored immature permanent teeth (Nowak et al., 2018; Plotino et al., 2008).

6.)BLEACHING DISCOLORED TEETH AFTER REGENERATIVE ENDODONTIC TREATMENT

Some studies report that discoloration occurs in teeth after RET (Kahler and Rossi-Fedele, 2016; Petrino et al., 2009). To minimize the risk of color change in crowns, the American Association of Endodontists recommends that when TAP is used during RET, the pulp chamber should be

covered with a bonding agent, and the blood clot formed during treatment should be sealed with MTA or alternative bioceramics or other calcium silicate-based materials (American Association of Endodontists, 2016).

Treatment options used to reduce or eliminate tooth discoloration after RET include masking discoloration using composite resin or internal whitening to reduce color changes (D’Mello and Moloney, 2017). Simple, applicable, and minimally invasive procedures should be considered as treatment options. The ideal option would be tooth whitening. However, the 2012 Cosmetic Products Safety Amendment Regulation permits the use of 0.1-6% hydrogen peroxide and other compounds or mixtures that release hydrogen peroxide only “for the purpose of treating or preventing a disease” in patients under 18 years old (Greenwall-Cohen et al., 2018).

In whitening methods aimed at eliminating or reducing discoloration, products generally containing hydrogen peroxide and its derivatives are used (Goldstein and Garber, 1995). Historically, different materials have been used depending on the type and severity of discoloration in teeth. These include primarily hydrogen peroxide, carbamide peroxide, sodium perborate, and non-peroxide-containing substances (Linda, 2001).

Various studies have been conducted to determine the treatment of discolored teeth based on the types of materials used in RET. In studies using sodium perborate with heat application, a greater degree of discoloration was observed (Kirchhoff et al., 2015; Küçükekenci et al., 2018).

In research conducted by Kirchhoff and colleagues regarding the whitening of discolored teeth after RET, the teeth were divided into two groups based on whether they had open or closed apices, and both groups received triple antibiotic paste (TAP), which was left on the teeth for three weeks. Measurements taken after three weeks of TAP on the teeth were designated as T1; measurements after the removal of TAP using NaOCl were designated as T2; and measurements after the application of sodium perborate paste were designated as T3, T4, and T5 for the 1st, 2nd, and 3rd weeks, respectively. A visible discoloration was observed at T1, while the color became lighter over time as the duration of sodium perborate application increased (T3 < T4 < T5) (Kirchhoff et al., 2015).

Another study conducted by İriboz and colleagues included 80 anterior teeth. They divided the teeth into two groups using minocycline paste and triple antibiotic paste. Sodium perborate was applied to the teeth, and the amount of discoloration was measured weekly during the four weeks the pastes were left in the canal. The whitening agent was activated using heat and ultrasonic waves at two different frequencies (30-60 Hz). Color changes in the teeth were measured between the 3rd and 7th days. Significant discoloration was detected in both groups after the application of

the pastes; however, no significant difference was found among the colors detected before whitening. During the whitening phase, although the group using minocycline paste showed more color change on the 3rd and 7th days, no significant color change was observed at the final measurement stage. When comparing the whitening techniques used, no significant differences were found between the techniques at the end of the study (İriboz et al., 2017).

Kucukekenci and colleagues defined their study groups as containing minocycline-based TAP, DAP, amoxicillin-based TAP, cefaclor-based TAP, doxycycline-based TAP, and a control group. They then randomly divided the teeth that were discolored due to the use of antibiotic pastes into two subgroups: one group received internal whitening using only H₂O₂, while the other group received H₂O₂ along with NdYAG laser treatment. The measurements showed discoloration in all groups except for the DAP and control groups. The minocycline-based TAP group exhibited significantly more discoloration than the other groups. The results of the whitening indicated that the thermocatalytic method provided greater whitening compared to the walking bleaching technique. However, no group returned to its original color after whitening (Kucukekenci et al., 2019).

In another study assessing the effect of MTA removal on discoloration, OrthoMTA was chosen as the coronal barrier material. In one group, part of the OrthoMTA was removed and covered with glass ionomer cement, while the OrthoMTA in the other group was left as initially placed. In this study, where carbamide peroxide was used as a whitening agent, no significant difference was found between the two groups after whitening. However, the group where OrthoMTA was covered with glass ionomer cement required fewer whitening sessions, and the average ΔE value in this group was found to be lower (Khedmat et al., 2021).

7.)CONCLUSION

In regenerative endodontic treatment, a current method applied due to the devitalization of immature permanent teeth caused by trauma and other reasons, discoloration occurs in teeth based on the materials used. Comprehensive research on the subject has concluded that the use of minocycline-containing triple antibiotic paste, the interaction of irrigation solutions used during treatment with each other and dentin, the use of MTA as a coronal barrier, and the clot formation providing the scaffold contribute to more discoloration than the other materials used.

REFERENCES

- Abbott, Paul V. (1998) "Apexification with calcium hydroxide-when should the dressing be changed? The case for regular dressing changes." *Australian Endodontic Journal* 24.1: 27-32. (n.d.).
- Aguiar, B. A., Frota, L. M. A., Taguatinga, D. T., Vivan, R. R., Camilleri, J., Duarte, M. A. H., & de Vasconcelos, B. C. (2019). Influence of ultrasonic agitation on bond strength, marginal adaptation, and tooth discoloration provided by three coronary barrier endodontic materials. *Clinical oral investigations*, 23(11), 4113–4122. <https://doi.org/10.1007/s00784-019-02850-y>
- Akbulut, Makbule Bilge, et al. (2017). "Tooth discoloration effects of calcium silicate based barrier materials used in revascularization and treatment with internal bleaching." *Journal of Dental Sciences* 12.4: 347-353. (n.d.).
- Akbulut MB, Terlemez A, Akman M, Buyukerkmen B, Guneser MB, Eldeniz AU. (2017). Tooth discoloration effects of calcium silicate based barrier materials used in revascularization and treatment with internal bleaching. *J Dent Sci.* 2017 Dec;12(4):347-353. (n.d.). <https://doi.org/10.1016/j.jds.2017.03.009>
- Akcay, M., Arslan, H., Yasa, B., Kavruk, F., & Yasa, E. (2014). Spectrophotometric analysis of crown discoloration induced by various antibiotic pastes used in revascularization. *Journal of endodontics*, 40(6), 845–848. <https://doi.org/10.1016/j.joen.2013.09.019>
- Alazmah, A. (2021). Primary teeth stains and discoloration: a review. *Journal of Child Science*, 11(01), e20-e27..
- Altun, N. B., & Turkyilmaz, A. (2024). Potential Crown Discoloration Induced by the Combination of Various Intracanal Medicaments and Scaffolds Applied in Regenerative Endodontic Therapy. *Nigerian journal of clinical practice*, 27(7), 897–904. https://doi.org/10.4103/njcp.njcp_126_24
- American Association of Endodontists (2016) AAE clinical considerations for a regenerative procedure. Revised 6-8-16. https://www.aae.org/uploadedfiles/publications_and_research/research/currentregenerativeendodontic-considerations.pdf. Accessed 30 July . (n.d.).
- Angelova Volponi, A., Zaugg, L. K., Neves, V., Liu, Y., & Sharpe, P. T. (2018). Tooth Repair and Regeneration. *Current oral health reports*, 5(4), 295–303. <https://doi.org/10.1007/s40496-018-0196-9>
- Araújo, P. R. S., Silva, L. B., Neto, A. P. D. S., Almeida de Arruda, J. A., Álvares, P. R., Sobral, A. P. V., Júnior, S. A., Leão, J. C., Braz da Silva, R., & Sampaio, G. C. (2017). Pulp Revascularization: A Literature Review. *The open dentistry journal*, 10, 48–56. <https://doi.org/10.2174/1874210601711010048>
- Arman, M., Khalilak, Z., Rajabi, M., Esnaashari, E., & Saati, K. (2015). In Vitro Spectrophotometry of Tooth Discoloration Induced by Tooth-Colored Mineral Trioxide Aggregate and Calcium-Enriched Mixture Cement. *Iranian endodontic journal*, 10(4), 226–230. <https://doi.org/10.7508/iej.2015.04.003>

- Banchs, F., & Trope, M. (2004). Revascularization of immature permanent teeth with apical periodontitis: new treatment protocol?. *Journal of endodontics*, 30(4), 196–200. <https://doi.org/10.1097/00004770-200404000-00003>
- Barao VAR, Coata RC, Shibli JA, Bertolini M, Souza JGS. American Association of Endodontists (AAE). Clinical considerations for a regenerative procedure. American Association of Endodontists. Scope of Endodontics : regenerative endodontics. *Journal of End.* (n.d.).
- Belobrov, I., & Parashos, P. (2011). Treatment of tooth discoloration after the use of white mineral trioxide aggregate. *Journal of endodontics*, 37(7), 1017–1020. <https://doi.org/10.1016/j.joen.2011.04.003>
- Bizhang, M., Heiden, A., Blunck, U., Zimmer, S., Seemann, R., & Roulet, J. F. (2003). Intracoronal bleaching of discolored non-vital teeth. *Operative dentistry*, 28(4), 334–340.
- Bonte, E., Beslot, A., Boukpepsi, T., & Lasfargues, J. J. (2015). MTA versus Ca(OH)₂ in apexification of non-vital immature permanent teeth: a randomized clinical trial comparison. *Clinical oral investigations*, 19(6), 1381–1388. <https://doi.org/10.1007/s00784-014-1348-5>
- Camilleri J. (2015). Staining Potential of Neo MTA Plus, MTA Plus, and Bio-dentine Used for Pulpotomy Procedures. *Journal of endodontics*, 41(7), 1139–1145. <https://doi.org/10.1016/j.joen.2015.02.032>
- Cehreli, Z. C., Isbitiren, B., Sara, S., & Erbas, G. (2011). Regenerative endodontic treatment (revascularization) of immature necrotic molars medicated with calcium hydroxide: a case series. *Journal of endodontics*, 37(9), 1327–1330. <https://doi.org/10.1016/j.joen.2011.05.033>
- Chaniotis A (2016) The use of a single-step regenerative approach for the treatment of a replanted mandibular central incisor with severe resorption. *International Endodontic Journal* 49, 802–12.
- Chu, S. J. (2004). Fundamentals of color: shade matching and communication in esthetic dentistry. (No Title)..
- Cvek M. (1992). Prognosis of luxated non-vital maxillary incisors treated with calcium hydroxide and filled with gutta-percha. A retrospective clinical study. *Endodontics & dental traumatology*, 8(2), 45–55. <https://doi.org/10.1111/j.1600-9657.1992.tb00228.x>
- D’Mello, G., & Moloney, L. (2017). Management of coronal discoloration following a regenerative endodontic procedure in a maxillary incisor. *Australian dental journal*, 62(1), 111–116. <https://doi.org/10.1111/adj.12462>
- Dahl, J. E., & Pallesen, U. (2003). Tooth bleaching--a critical review of the biological aspects. *Critical reviews in oral biology and medicine : an official publication of the American Association of Oral Biologists*, 14(4), 292–304. <https://doi.org/10.1177/154411130301400406>

- Dayan, D., Heifferman, A., Gorski, M., & Begleiter, A. (1983). Tooth discoloration--extrinsic and intrinsic factors. *Quintessence international, dental digest*, 14(2), 195–199.
- de Jesus Oliveira LS, Silva PFD, de Figueiredo FED, Brito-Junior M, de Sousa Neto MD, Faria-E-Silva AL. In vitro evaluation of tooth discoloration induced by regenerative endodontic therapy and the effectiveness of the walking bleach technique. *Int J Esthe.* (n.d.).
- Dettwiler, C. A., Walter, M., Zaugg, L. K., Lenherr, P., Weiger, R., & Krastl, G. (2016). In vitro assessment of the tooth staining potential of endodontic materials in a bovine tooth model. *Dental traumatology : official publication of International Association for Dental Traumatology*, 32(6), 480–487. <https://doi.org/10.1111/edt.12285>
- Diogenes A, Henry MA, Teixeira FB, Hargreaves KM (2013) An update on clinical regenerative endodontics. *Endodontic Topics* 28,2–23.
- Doğan, D. A., & Yüzügüllü, B. (2011). Renk seçiminde güncel teknolojik gelişmeler. *Atatürk Üniversitesi Diş Hekimliği Fakültesi Dergisi*, 2011(4), 65-72.
- European Society of Endodontology (ESE) (2016) European Society of Endodontology position statement: revitalization procedures. *International Endodontic Journal* 49, 717–23.
- Fagogeni, I., Metlerska, J., Falgowski, T., Górski, M., Lipski, M., & Nowicka, A. (2022). Effectiveness of Teeth Whitening after Regenerative Endodontics Procedures: An In Vitro Study. *Journal of clinical medicine*, 11(23), 7016. <https://doi.org/10.3390/jcm11237016>
- Feinman, R.A., Mandray, G. & Yarborough, D. (1991) Chemical, optical, and physiologic mechanisms of bleaching products: a review. *Practical Periodontics and Aesthetic Dentistry*, 3, 32– 37. (n.d.).
- Felman, D., & Parashos, P. (2013). Coronal tooth discoloration and white mineral trioxide aggregate. *Journal of endodontics*, 39(4), 484–487. <https://doi.org/10.1016/j.joen.2012.11.053>
- Flanagan T. A. (2014). What can cause the pulps of immature, permanent teeth with open apices to become necrotic and what treatment options are available for these teeth. *Australian endodontic journal : the journal of the Australian Society of Endodontology Inc*, 40(3), 95–100. <https://doi.org/10.1111/aej.1208>
- Frank A. L. (1966). Therapy for the divergent pulpless tooth by continued apical formation. *Journal of the American Dental Association* (1939), 72(1), 87–93. <https://doi.org/10.14219/jada.archive.1966.0017>
- Fuks A. B. (2000). Pulp therapy for the primary and young permanent dentitions. *Dental clinics of North America*, 44(3), 571–vii.
- Fundaoğlu Küçükekenci, F., Çakıcı, F., & Küçükekenci, A. S. (2019). Spectrophotometric analysis of discoloration and internal bleaching after use of diffe-

- rent antibiotic pastes. *Clinical oral investigations*, 23(1), 161–167. <https://doi.org/10.1007/s00784-018-2422-1>
- Galler K. M. (2016). Clinical procedures for revitalization: current knowledge and considerations. *International endodontic journal*, 49(10), 926–936. <https://doi.org/10.1111/iej.12606>
- Garcia-Godoy, F., & Murray, P. E. (2012). Recommendations for using regenerative endodontic procedures in permanent immature traumatized teeth. *Dental traumatology : official publication of International Association for Dental Traumatology*, 28(1), 33–41. <https://doi.org/10.1111/j.1600-9657.2011.01044.x>
- Goldstein, R.E. & Garber, D.A. (1995) Complete dental bleaching. Berlin: Quintessence. (n.d.).
- Greenwall-Cohen, J., Greenwall, L., Haywood, V., & Harley, K. (2018). Tooth whitening for the under-18-year-old patient. *British dental journal*, 225(1), 19–26. <https://doi.org/10.1038/sj.bdj.2018.527>
- Greenwall, L. (Ed.). (2001). Bleaching techniques in restorative dentistry: An illustrated guide. CRC Press.
- Gutiérrez, J. H., & Guzmán, M. (1968). Tooth discoloration in endodontic procedures. *Oral surgery, oral medicine, and oral pathology*, 26(5), 706–711. [https://doi.org/10.1016/0030-4220\(68\)90443-x](https://doi.org/10.1016/0030-4220(68)90443-x)
- Gürel, G. (2004). Porselen laminat veneerler bilim ve sanatı. *Quintessence*, 126-129.
- Hattab, F. N., Qudeimat, M. A., & al-Rimawi, H. S. (1999). Dental discoloration: an overview. *Journal of esthetic dentistry*, 11(6), 291–310. <https://doi.org/10.1111/j.1708-8240.1999.tb00413.x>
- Heymann, H. O., & Ritter, A. V. (2018). Additional conservative esthetic procedures. In *Sturdevant's Art and Science of Operative Dentistry* (pp. 264-305). Elsevier.
- Hobo, S., & Iwata, T. (1985). A new laminate veneer technique using a castable apatite ceramic material. I. Theoretical considerations. *Quintessence International*, 16(7). [https://www.aae.org/specialty/wpcontent/uploads/sites/2/2021/08/ClinicalConsiderationsApprovedByREC062921 .pdf](https://www.aae.org/specialty/wpcontent/uploads/sites/2/2021/08/ClinicalConsiderationsApprovedByREC062921.pdf). Accessed 25.10.2022. (n.d.).
- Ioannidis, K., Mistakidis, I., Beltes, P., & Karagiannis, V. (2013). Spectrophotometric analysis of coronal discoloration induced by grey and white MTA. *International endodontic journal*, 46(2), 137–144. <https://doi.org/10.1111/j.1365-2591.2012.02098.x>
- Iriboz, E., Öztürk, B. A., Körklü, S., Tarcin, B., Berker, Y. G., & Öveçoğlu, H. S. (2017). Comparison of intracoronal bleaching methods on teeth discolored by different antibiotic pastes. *Nigerian journal of clinical practice*, 20(6), 700–706. <https://doi.org/10.4103/1119-3077.183247>

- Iwaya, S. I., Ikawa, M., & Kubota, M. (2001). Revascularization of an immature permanent tooth with apical periodontitis and sinus tract. *Dental traumatology : official publication of International Association for Dental Traumatology*, 17(4), 185–187. <https://doi.org/10.1034/j.1600-9657.2001.017004185.x>
- Jang, J. H., Kang, M., Ahn, S., Kim, S., Kim, W., Kim, Y., & Kim, E. (2013). Tooth discoloration after the use of new pozzolan cement (Endocem) and mineral trioxide aggregate and the effects of internal bleaching. *Journal of endodontics*, 39(12), 1598–1602. <https://doi.org/10.1016/j.joen.2013.08.035>
- Jeeruphan, T., Jantarat, J., Yanpiset, K., Suwannapan, L., Khewsawai, P., & Hargreaves, K. M. (2012). Mahidol study 1: comparison of radiographic and survival outcomes of immature teeth treated with either regenerative endodontic or apexification methods: a retrospective study. *Journal of endodontics*, 38(10), 1330–1336. <https://doi.org/10.1016/j.joen.2012.06.028>
- Joiner A. (2004). Tooth colour: a review of the literature. *Journal of dentistry*, 32 Suppl 1, 3–12. <https://doi.org/10.1016/j.jdent.2003.10.013>
- Kahler, Bill, and Giampiero Rossi-Fedele. “A review of tooth discoloration after regenerative endodontic therapy.” *Journal of endodontics* 42.4 (2016): 563-569. (n.d.).
- Kahler B, Rossi-Fedele G (2016) A review of tooth discoloration after regenerative endodontic therapy. *J Endod* 42, 563-569. (n.d.).
- Kang, S. H., Shin, Y. S., Lee, H. S., Kim, S. O., Shin, Y., Jung, I. Y., & Song, J. S. (2015). Color changes of teeth after treatment with various mineral trioxide aggregate-based materials: an ex vivo study. *Journal of endodontics*, 41(5), 737–741. <https://doi.org/10.1016/j.joen.2015.01.019>
- Karabucak, B., Li, D., Lim, J., & Iqbal, M. (2005). Vital pulp therapy with mineral trioxide aggregate. *Dental traumatology : official publication of International Association for Dental Traumatology*, 21(4), 240–243. <https://doi.org/10.1111/j.1600-9657.2005.00306.x>
- Karadaş M & Seven N. (2014). Vital Tooth Bleaching. *Atatürk Üniversitesi Diş Hekimliği Fakültesi 60 Dergisi*, 24(3):126-135. Doi: <https://doi.org/10.17567/dfd.11729>. (n.d.).
- Khedmat, S., Ahmadi, E., Meraji, N., & Fallah, Z. F. (2021). Colorimetric Comparison of Internal Bleaching with and without Removing Mineral Trioxide Aggregate (MTA) on Induced Coronal Tooth Discoloration by MTA. *International journal of dentistry*, 2021, 8319986. <https://doi.org/10.1155/2021/8319986>
- Kim, J. H., Kim, Y., Shin, S. J., Park, J. W., & Jung, I. Y. (2010). Tooth discoloration of immature permanent incisor associated with triple antibiotic therapy: a case report. *Journal of endodontics*, 36(6), 1086–1091. <https://doi.org/10.1016/j.joen.2010.03.031>
- Kirchhoff, A. L., Raldi, D. P., Salles, A. C., Cunha, R. S., & Mello, I. (2015). Tooth discoloration and internal bleaching after the use of triple antibio-

- tic paste. *International endodontic journal*, 48(12), 1181–1187. <https://doi.org/10.1111/iej.12423>
- Kohli, M. R., Yamaguchi, M., Setzer, F. C., & Karabucak, B. (2015). Spectrophotometric Analysis of Coronal Tooth Discoloration Induced by Various Bioceramic Cements and Other Endodontic Materials. *Journal of endodontics*, 41(11), 1862–1866. <https://doi.org/10.1016/j.joen.2015.07.003>
- Korkmaz, C. (2015). Tam seramiklerin dişhekimliğindeki yeri. *Atatürk Üniversitesi Diş Hekimliği Fakültesi Dergisi*, 24(Supplement 8), 136-140.
- Fundaoğlu Küçükekenci, F., Çakıcı, F., & Küçükekenci, A. S. (2019). Spectrophotometric analysis of discoloration and internal bleaching after use of different antibiotic pastes. *Clinical oral investigations*, 23(1), 161–167. <https://doi.org/10.1007/s00784-018-2422-1>
- Lee, J. K., Kwak, S. W., Ha, J. H., Lee, W., & Kim, H. C. (2017). Physicochemical Properties of Epoxy Resin-Based and Bioceramic-Based Root Canal Sealers. *Bioinorganic chemistry and applications*, 2017, 2582849. <https://doi.org/10.1155/2017/2582849>
- Lenherr, P., Allgayer, N., Weiger, R., Filippi, A., Attin, T., & Krastl, G. (2012). Tooth discoloration induced by endodontic materials: a laboratory study. *International endodontic journal*, 45(10), 942–949. <https://doi.org/10.1111/j.1365-2591.2012.02053.x>
- Lin, J. C., Lu, J. X., Zeng, Q., Zhao, W., Li, W. Q., & Ling, J. Q. (2016). Comparison of mineral trioxide aggregate and calcium hydroxide for apexification of immature permanent teeth: A systematic review and meta-analysis. *Journal of the Formosan Medical Association = Taiwan yi zhi*, 115(7), 523–530. <https://doi.org/10.1016/j.jfma.2016.01.010>
- Marciano, M. A., Costa, R. M., Camilleri, J., Mondelli, R. F., Guimarães, B. M., & Duarte, M. A. (2014). Assessment of color stability of white mineral trioxide aggregate angelus and bismuth oxide in contact with tooth structure. *Journal of endodontics*, 40(8), 1235–1240. <https://doi.org/10.1016/j.joen.2014.01.044>
- McCabe P (2015) Revascularization of an immature tooth with apical periodontitis using a single visit protocol: a case report. *International Endodontic Journal* 48, 484–97.
- Mishra, D., Arya, A., Vamseekrishna, K. V. N., Jahangeer, B., Sachdeva, M., & Moses, A. (2024). Evaluation and Comparative Analysis of Coronal Tooth Discoloration Induced by Four Endodontic Biomaterials Utilized in Regenerative Endodontic Procedures: An Ex-vivo Study. *Cureus*, 16(6), e62874. <https://doi.org/10.7759/cureus.62874>
- Murray, P. E., Garcia-Godoy, F., & Hargreaves, K. M. (2007). Regenerative endodontics: a review of current status and a call for action. *Journal of endodontics*, 33(4), 377–390. <https://doi.org/10.1016/j.joen.2006.09.013>

- Nagata, J. Y., Gomes, B. P., Rocha Lima, T. F., Murakami, L. S., de Faria, D. E., Campos, G. R., de Souza-Filho, F. J., & Soares, A. de J. (2014). Traumatized immature teeth treated with 2 protocols of pulp revascularization. *Journal of endodontics*, 40(5), 606–612. <https://doi.org/10.1016/j.joen.2014.01.032>
- Naik, S., & Hegde, A. H. (2005). Mineral trioxide aggregate as a pulpotomy agent in primary molars: an in vivo study. *Journal of the Indian Society of Pedodontics and Preventive Dentistry*, 23(1), 13–16. <https://doi.org/10.4103/0970-4388.16020>
- Nathoo S. A. (1997). The chemistry and mechanisms of extrinsic and intrinsic discoloration. *Journal of the American Dental Association* (1939), 128 Suppl, 6S–10S. <https://doi.org/10.14219/jada.archive.1997.0428>
- Nosrat, A., Li, K. L., Vir, K., Hicks, M. L., & Fouad, A. F. (2013). Is pulp regeneration necessary for root maturation?. *Journal of endodontics*, 39(10), 1291–1295. <https://doi.org/10.1016/j.joen.2013.06.019>
- Nowak, Arthur J., et al., eds. *Pediatric Dentistry: Pediatric Dentistry-E-Book*. Elsevier Health Sciences, 2018. (n.d.).
- Nowak A, Christensen JR, Mabry TR, Townsend JA, Wells MH. *Pediatric Dentistry-E-Book: infancy through adolescence*. Elsevier Health Sciences; 2018. (n.d.).
- Oliveira, L. V., da Silva, G. R., Souza, G. L., Magalhães, T. E. A., Barbosa, G. L. R., Turrioni, A. P., & Moura, C. C. G. (2020). A laboratory evaluation of cell viability, radiopacity and tooth discoloration induced by regenerative endodontic materials. *International endodontic journal*, 53(8), 1140–1152. <https://doi.org/10.1111/iej.13308>
- Palma, P. J., Marques, J. A., Falacho, R. I., Correia, E., Vinagre, A., Santos, J. M., & Ramos, J. C. (2019). Six-Month Color Stability Assessment of Two Calcium Silicate-Based Cements Used in Regenerative Endodontic Procedures. *Journal of functional biomaterials*, 10(1), 14. <https://doi.org/10.3390/jfb10010014>
- Parolia, A., & Shetty, N. (2010). Regenerative Endodontics: A Review. *Malaysian Dental Journal*, 31(2)..
- Peters O. A. (2004). Current challenges and concepts in the preparation of root canal systems: a review. *Journal of endodontics*, 30(8), 559–567. <https://doi.org/10.1097/01.don.0000129039.59003.9d>
- Petrino, J. A., Boda, K. K., Shambarger, S., Bowles, W. R., & McClanahan, S. B. (2010). Challenges in regenerative endodontics: a case series. *Journal of endodontics*, 36(3), 536–541. <https://doi.org/10.1016/j.joen.2009.10.006>
- Peumans, M., Van Meerbeek, B., Lambrechts, P., & Vanherle, G. (2000). Porcelain veneers: a review of the literature. *Journal of dentistry*, 28(3), 163–177. [https://doi.org/10.1016/s0300-5712\(99\)00066-4](https://doi.org/10.1016/s0300-5712(99)00066-4).

- Pizzamiglio E. (1991). A color selection technique. *The Journal of prosthetic dentistry*, 66(5), 592–596. [https://doi.org/10.1016/0022-3913\(91\)90435-y](https://doi.org/10.1016/0022-3913(91)90435-y)
- Plotino, G., Buono, L., Grande, N.M., Pameijer, C.H. & Somma, F. (2008) Non-vital tooth bleaching: a review of the literature and clinical procedures. *Journal of Endodontics*, 34, 394– 407. (n.d.).
- Poly, A., Marques, F., Fidel, S. R., Monnerat, A. F., & Sassone, L. M. (2019). Ability of two single-step restorative materials to avoid crown darkening caused by intracanal minocycline paste. *Clinical oral investigations*, 23(3), 1281–1286. <https://doi.org/10.1007/s00784-018-2557-0>
- Porciuncula de Almeida, M., Angelo da Cunha Neto, M., Paula Pinto, K., Rivera Fidel, S., João Nogueira Leal Silva, E., & Moura Sassone, L. (2021). Antibacterial efficacy and discolouration potential of antibiotic pastes with macrogol for regenerative endodontic therapy. *Australian endodontic journal : the journal of the Australian Society of Endodontology Inc*, 47(2), 157–162. <https://doi.org/10.1111/aej.12438>
- Rosenstiel, S. F., & Land, M. F. (Eds.). (2015). *Contemporary Fixed Prosthodontics-E-Book: Contemporary Fixed Prosthodontics-E-Book*. Elsevier Health Sciences.
- Ruparel, N. B., Teixeira, F. B., Ferraz, C. C., & Diogenes, A. (2012). Direct effect of intracanal medicaments on survival of stem cells of the apical papilla. *Journal of endodontics*, 38(10), 1372–1375. <https://doi.org/10.1016/j.joen.2012.06.018>
- Saba, C., Solidani, M., Berlutti, F., Vestri, A., Ottolenghi, L., & Polimeni, A. (2006). Black stains in the mixed dentition: a PCR microbiological study of the etiopathogenic bacteria. *The Journal of clinical pediatric dentistry*, 30(3), 219–224. <https://doi.org/10.17796/jcpd.30.3.q1561155x22u0774>
- Santos, L. G., Felipe, W. T., Souza, B. D., Konrath, A. C., Cordeiro, M. M., & Felipe, M. C. (2017). Crown discoloration promoted by materials used in regenerative endodontic procedures and effect of dental bleaching: spectrophotometric analysis. *Journal of applied oral science : revista FOB*, 25(2), 234–242. <https://doi.org/10.1590/1678-77572016-0398>
- Sarkar, N. K., Caicedo, R., Ritwik, P., Moiseyeva, R., & Kawashima, I. (2005). Physicochemical basis of the biologic properties of mineral trioxide aggregate. *Journal of endodontics*, 31(2), 97–100. <https://doi.org/10.1097/01.don.0000133155.04468.41>
- Schilder H. (1974). Cleaning and shaping the root canal. *Dental clinics of North America*, 18(2), 269–296..
- Setzer, F. (2020) Bleaching procedures. In: L.H. Berman & K.M. Hargreaves (Eds.) *Pathways of the pulp*, 12th edition. St Louis, MI: Elsevier, pp. e2–e22. (n.d.).

- Shin S, Albert J, Mortman R (2009) One step pulp revascularization treatment of an immature permanent tooth with chronic periapical abscess: a case report. *International Endodontic Journal* 42, 1118–26.
- Shokouhinejad, N., Khoshkhounejad, M., Alikhasi, M., Bagheri, P., & Camilleri, J. (2018). Prevention of coronal discoloration induced by regenerative endodontic treatment in an ex vivo model. *Clinical oral investigations*, 22(4), 1725–1731. <https://doi.org/10.1007/s00784-017-2266-0>
- Shokouhinejad, N., Nekoofar, M. H., Pirmoazen, S., Shamshiri, A. R., & Dummer, P. M. (2016). Evaluation and Comparison of Occurrence of Tooth Discoloration after the Application of Various Calcium Silicate-based Cements: An Ex Vivo Study. *Journal of endodontics*, 42(1), 140–144. <https://doi.org/10.1016/j.joen.2015.08.034>
- Shokouhinejad, N., Razmi, H., Farbod, M., Alikhasi, M., & Camilleri, J. (2019). Coronal tooth discoloration induced by regenerative endodontic treatment using different scaffolds and intracanal coronal barriers: a 6-month ex vivo study. *Restorative dentistry & endodontics*, 44(3), e25. <https://doi.org/10.5395/rde.2019.44.e25>
- Shokouhinejad, N., Razmi, H., Farbod, M., Alikhasi, M., & Camilleri, J. (2019). Coronal tooth discoloration induced by regenerative endodontic treatment using different scaffolds and intracanal coronal barriers: a 6-month ex vivo study. *Restorative dentistry & endodontics*, 44(3), e25. <https://doi.org/10.5395/rde.2019.44.e25>
- Shokouhinejad, N., Tahun, I. A., Tahan, S. S., Mohandes, F., Nekoofar, M. H., & Dummer, P. M. H. (2023). Microstructure and color stability of calcium silicate-based dental materials exposed to blood or platelet-rich fibrin. *Clinical oral investigations*, 27(3), 1193–1206. <https://doi.org/10.1007/s00784-022-04733-1>
- Thäter, M., & Maréchaux, S. C. (1988). Induced root apexification following traumatic injuries of the pulp in children: follow-up study. *ASDC journal of dentistry for children*, 55(3), 190–195..
- The Cosmetic Products (Safety) (Amendment) Regulations 2012. Available online: <http://www.legislation.gov.uk/ukxi/2012/2263/made> (accessed on 26 February 2020). (n.d.).
- Timmerman, A., & Parashos, P. (2018). Bleaching of a Discolored Tooth with Retrieval of Remnants after Successful Regenerative Endodontics. *Journal of endodontics*, 44(1), 93–97. <https://doi.org/10.1016/j.joen.2017.08.032>
- Topcuoglu G, Topcuoglu HS (2016) Regenerative endodontic therapy in a single visit using platelet-rich plasma and Biodentine in necrotic and asymptomatic immature molar teeth: a report of 3 cases. *Journal of Endodontics* 42, 13446.
- Torabinejad, M., Higa, R. K., McKendry, D. J., & Pitt Ford, T. R. (1994). Dye leakage of four root end filling materials: effects of blood contamination.

- tion. *Journal of endodontics*, 20(4), 159–163. [https://doi.org/10.1016/S0099-2399\(06\)80326-2](https://doi.org/10.1016/S0099-2399(06)80326-2)
- Torabinejad, M., Parirokh, M., & Dummer, P. M. H. (2018). Mineral trioxide aggregate and other bioactive endodontic cements: an updated overview - part II: other clinical applications and complications. *International endodontic journal*, 51(3), 284–317. <https://doi.org/10.1111/iej.12843>
- TR, P. F. (1996). Apexification and apexogenesis. *Principles and practice of endodontics*, 373-384.
- Wang, X., Thibodeau, B., Trope, M., Lin, L. M., & Huang, G. T. (2010). Histologic characterization of regenerated tissues in canal space after the revitalization/revascularization procedure of immature dog teeth with apical periodontitis. *Journal of endodontics*, 36(1), 56–63. <https://doi.org/10.1016/j.joen.2009.09.039>
- Watts, A., & Addy, M. (2001). Tooth discolouration and staining: a review of the literature. *British dental journal*, 190(6), 309–316. <https://doi.org/10.1038/sj.bdj.4800959>
- Weiger, R., Kuhn, A. & Löst, C. (1994a) In vitro comparison of various types of sodium perborate used for intracoronal bleaching of discolored teeth. *Journal of Endodontics*, 20, 338– 341. (n.d.).
- Yoldaş, S. E., Bani, M., Atabek, D., & Bodur, H. (2016). Comparison of the Potential Discoloration Effect of Bioaggregate, Biodentine, and White Mineral Trioxide Aggregate on Bovine Teeth: In Vitro Research. *Journal of endodontics*, 42(12), 1815–1818. <https://doi.org/10.1016/j.joen.2016.08.020>
- Žižka, R., Šedý, J., Gregor, L., & Voborná, I. (2018). *Discoloration after Regenerative Endodontic Procedures: A Critical Review*. *Iranian endodontic journal*, 13(3), 278–284. <https://doi.org/10.22037/iej.v13i3.21271>

CHAPTER 5

EFFECT OF HEAD AND NECK RADIATION THERAPY ON ENDODONTIC TREATMENT

Özgün GÜLDEREN¹

Şebnem DURUKAN²

Esmâ SARIÇAM³

1 Research Assistant Ankara Yıldırım Beyazıt University Faculty of Dentistry 0009-0000-6971-435X

2 Research Assistant Ankara Yıldırım Beyazıt University Faculty of Dentistry 0009-0000-6971-435X

3 Associate Professor Ankara Yıldırım Beyazıt University Faculty of Dentistry 0000-0001-7701-4214

1.) Development of Radiotherapy

Physics played a crucial role in the early development of radiation therapy as an anticancer treatment; the goal of the treatment was to increase the amount and quality of radiation that could be delivered to a tumor. Early work in experimental radiation oncology progressed from the use of massive single doses to the use of small doses of radiation to kill tumor cells and protect standart tissues (Grubbé, 1933).

Wilhelm Conrad Röntgen made the discovery of X-rays in Germany in 1895, while Henry Becquerel, a French physicist, found natural radioactivity a few months later while researching uranium salts. These two significant occasions helped to usher in a new chapter in scientific history. Clinical radiation therapy was created sixty days following the discovery of X-rays. In January 1896, Emil Grubbé used X-rays to treat advanced ulcerated breast cancer in Chicago. Over the course of the following century, advancements in radiation physics, chemistry, and biology influenced clinical methods for creating anticancer therapies that are more precise, efficient, and safe (Grubbé, 1933).

In 1898, Pierre and Marie Curie discovered the radioactive substances polonium and radium. This discovery was presented at the Paris Academy of Sciences on January 26, 1898. Freund (1903) and Kienböck (1900) from Austria, Despeignes (1896), Danlos and Bloch (1901) from France, Albers-Schönberg and Strebul (1903) from Germany are among the important names of radiotherapy. The first brachytherapy trials started with radium, and examination of the records of that period leads us to names such as Walsh from England (1897), Albers-Schönberg from Germany (1903) and Belot from France (1904). In 1899, Stenbeck in Stockholm treated a female patient with basal cell carcinoma of the nose with X-rays (Uzel, 1999).

One of the most popular cancer treatment options is radiation therapy. In the treatment of hematologic malignancies and solid tumors, it is frequently chosen. Although it is primarily used to treat malignant tumors, benign disorders are also routinely treated with it. It frequently works in tandem with chemotherapy and surgery (Zeman et al., 2020).

Over the past 25 years, there have been significant advancements in the use of radiation therapy to treat certain tumor types, frequently coinciding with developments in medical or surgical oncology as well as improved diagnostic methods. The extensive adoption of breast-conserving surgery starting in the late 1970s is among the best examples. In the 1960s and 1970s, the first reports of retrospective examinations of breast-conserving therapies with megavolt radiation techniques appeared (Russell and Bartelink, 1999).

1.1.) Ionizing Radiation

Ionizing radiation is a term used for radiation that causes an electron to be detached from an atom or molecule, resulting in ionization (Özalpan, 2001). Ionizing radiation occurs in two different ways:

a) Electromagnetic radiation

Electromagnetic radiation, which includes gamma and X-rays, does not directly harm living things chemically or biologically. On the other hand, when they travel through a certain environment, they are absorbed and release their energy in the form of rapidly moving electrons via processes like photoelectricity and Compton.

b) Particle radiation

This form of radiation using electrons, protons, alpha particles, neutrons and high-energy heavy ions is generally used for experimental studies (Kumar et al., 2023; Moss and Cox, 1994).

1.2.) Mechanisms of Radiation-Induced Cell Death

The most important effect of radiotherapy on cells is through deoxyribonucleic acid (DNA). In addition, some protein and lipid-based enzymes that have critical functions in the cell membrane are also severely affected by irradiation (Kumar et al., 2023). Ionizing radiation causes damage to cell DNA in two different ways, direct or indirect. In direct DNA damage, the energy of photons absorbed by the tissue directly ionizes the chemical bonds between the bases that make up the DNA and this leads to DNA breaks. In indirect DNA damage, ionizing radiation causes ionization of water molecules in the cell and the hydroxyl radicals (OH⁻) produced because of ionization cause DNA breaks. Some of these DNA breaks are sublethal breaks that cannot cause death. Normal cells are better able to mend sublethal fractures than are cancerous cells. Sublethal breaches lead malignant cells to die since the majority of malignant cells lack this capacity to repair damage (Moss and Cox, 1994).

1.3.) Clinical Use of Radiotherapy

Radiation therapy is used in two different ways: palliative or curative. Palliative care involves a shorter life expectancy for the patient and the short-term administration of high doses of radiation therapy to lessen the discomfort brought on by cancer-related symptoms. A patient receiving cu-

rative treatment might expect to live longer and suffer some adverse effects (Ballas and Shah, 2011).

A interdisciplinary field that exists at the intersection of several disciplines, including physics, chemistry, biology, and medicine, is radiation oncology. The biological properties of the tumor and normal tissues, the kind of radiation, the dose schedule, the delivery method, and other intricate considerations all affect the clinical result. High-energy photons (6-25MV) are utilized in most clinical radiotherapy treatments for cancer. These photons shield the skin from radiation exposure and store energy deep within tissue. The radiation dose is administered in daily fractions of 1.8–2 Gray (Gy) for 6–8 weeks as a curative treatment (Delaney et al., 2005).

1.3.1.) Combined Treatment Methods

a) Preoperative radiation therapy:

It is a treatment method to eradicate microscopic or subclinical disease outside the surgical resection margin. It reduces tumor cell implantation by decreasing the number of viable cells in the operation area. The biggest disadvantage of this treatment is that it adversely affects the healing of normal tissues (Ballas and Shah, 2011).

b) Postoperative radiation therapy:

It aims to eliminate residual tumor at the surgical site by disrupting subclinical foci of tumor cells after surgery. The disadvantage is that its application requires the completion of surgical wound healing, during which radiation therapy is delayed (Ballas and Shah, 2011).

c) Radiotherapy and chemotherapy:

When the two treatment methods are used in combination, their effects on tumors or normal tissues are greater than when used alone (Ballas and Shah, 2011).

d) Integrated multi-modality cancer management:

It involves combining two or more therapy methods in order to increase patient survival and enhance tumor control. For example, large tumors or metastatic lymph nodes are treated with surgery or radiotherapy; regional microdissemination is treated with radiotherapy; and disseminated subclinical disease is treated with chemotherapy (Ballas and Shah, 2011).

1.3.2.) Application Techniques of Radiotherapy

a) External treatment (external beam fractionated radiation therapy): The most clinically recommended course of action is this one. Beams are applied externally to the tumor tissue. Intensity modulated radiation therapy (IMRT) or 3D conformal radiotherapy are the methods used today. Radiation therapy is planned so that the highest radiation dose reaches the tumorous tissues and the lowest amount reaches the healthy tissues (Zeman et al., 2020).

b) Brachytherapy: Refers to treatment administered over a short distance. The source of radioactivity is positioned either inside the tumor or extremely near to it. It is applied as a superficial mold, interstitially, intracavitary or intraluminal (Bourland, 2012).

c) Stereotactic radiosurgery: A special form of external radiotherapy. In this method, multiple beams of radiation from different angles are directed at a pre-marked target volume. High doses are achieved in the overlap region of the beams. A rapid dose drop occurs in normal tissues outside the target volume. It provides significant advantages over other radiotherapy techniques in dose distribution, especially in target volumes smaller than 4 cm. On the other hand, conformality decreases as tumor size increases (Yazıcı et al., 2011).

d) Intraoperative radiotherapy: It is the providing the tumor with high radiation in a single dose to ensure local control during the surgical procedure (Zeman et al., 2020).

2.) Radiotherapy in Head and Neck Cancers

Malignancies of the head and neck include of the lips, oral cavity, oropharynx, hypopharynx, tonsils, salivary glands, nasopharynx, nose, paranasal sinuses and middle ear (Kamangar et al., 2006). It is squamous cell carcinoma that is the most prevalent form of cancer (Cohen et al., 2018). With 890,000 new cases and 450,000 deaths from head and neck cancer in 2018, it was ranked as the seventh most prevalent cancer type globally (Bray et al., 2018). The Turkish Statistical Institute's 2016 statistics on cancer indicates that among the 10 most prevalent cancer forms in all age categories in our nation, laryngeal cancer, one of the head and neck cancers, ranks ninth in men (T.C. Ministry of Health, 2016).

Demographic, behavioral and environmental factors are connected to the risk of cancer of the head and neck. Major risk factors incorporate usage of tobacco products, alcohol, viral infections [Epstein Barr virus (EBV), human papillomavirus (HPV), hepatitis C virus (HCV)], immunodeficiency, occupational exposure (perchloroethylene, asbestos, pesticides,

polycyclic aromatic hydrocarbons, plastic and rubber products, ethanol, formaldehyde, cement, etc.), radiation, oral health, nutritional style, old age and genetics, radiation, oral health, diet, aging and genetics (Rettig and D'Souza, 2015). In the management of malignancies of the head and neck, radiotherapy is an important therapy method that is frequently either by itself or in conjunction with chemotherapy and surgery (Çitlak and Kapucu, 2017).

The critical crucial structures in this area make it technically very challenging to perform radiation treatment for head and neck cancers. Secondary consequences of this treatment are the destruction of teeth, leading to loss of oral function. This severely reduces quality of life (Lieshout and Bots, 2014). After surgery, a total dose of 55–60 Gy is administered to the salivary glands in cases of head and neck cancer, with daily 2 Gy fractions applied at a depth of 5 cm to ensure little residual illness. 45–50 Gy of radiation is administered as preoperative radiotherapy to the neck and hypopharynx. In postoperative radiotherapy, reciprocal lateral areas extending from the primary tumor to the skull base are exposed to radiation. The dose used for postoperative radiotherapy is 70-75 Gy. In the larynx region, a total dose between 55-66 Gy is generally recommended for T1 tumors (limited tumor), while doses between 60-70 Gy are considered adequate for T2 tumors (tumors that have spread to the adjacent area) (Engin and Erişen, 2003; Gemici et al., 2004). In tumors of the tonsillar fossa and faucial arch T1 (tumors under two centimeters in size) and T2 (tumors measuring two to four centimeters), external radiotherapy alone with 60-75 Gy provides effective tumor control (Stimson et al., 1997). The commonly used daily dose is conventional fractionation characterized by radiotherapy 5 days a week with 1.8-2 Gy per day (Engin and Erişen, 2003; Gemici et al., 2004; Uzal, 1995).

2.1.) Complications in Head and Neck Cancers Following Radiotherapy

The most typical systemic complications of radiotherapy are fatigue, skin changes, dry mouth, mucositis, taste varies, pain in the mouth/throat, dysphagia (difficulty swallowing), odynophagia (painful swallowing), anorexia, nausea, vomiting and emotional changes (anxiety, depression, fear, stress, loneliness, loss of control) (Ertem et al., 2009).

When patients with head and neck cancer receive radiation, mucositis, decreased taste, salivation, erythema or desquamation of the skin may occur in the early period, while complications such as atrophy, telangiectasia, ulceration, fibrosis, trismus, edema and necrosis of the mucous membranes and skin may appear in the late period. Patients undergoing cancer treat-

ment may develop temporomandibular dysfunction, which manifests as myofascial pain, headache, jaw joint pain or ear pain. It does not seem to be a consequence of cancer treatment in general but is more likely to occur with parafunctional habits (teeth clenching and grinding) connected to psychological stress and sleep dysfunction (Dreizen et al., 1977; Hancock and Epstein, 2003; Scully et al., 2004).

According to a study by Akkaş et al., 82% of patients with grade 1-2 mucositis, 90% of patients with radiotherapy-induced dry mouth, and 95% of patients who lost weight experienced these side effects (Akkaş et al., 2013). Haefner et al. conducted a retrospective research on 238 patients who had radiation therapy. The study found that during the acute phase, dermatitis developed in 69 individuals and dysphagia in 131 patients (Haefner et al., 2015). According to a study by Karthikeyan et al. including 121 cancer patients undergoing treatment, 45% of patients receiving radiation showed signs of extreme weariness (Karthikeyan et al., 2012).

2.2.) Effects of Radiotherapy on the Oral Tissues

Oral complications related to cancer treatments may develop acutely during or immediately after treatment; sometimes cancer treatment may cause oral problems that last for years. According to the “National Cancer Institute Common Toxicity Criteria (NCI-CTC)”, side effects that develop within 90 days from the start of radiotherapy are defined as acute, while those that develop after 90 days are defined as late side effects. Within the first three years after a head or neck cancer diagnosis, the majority of late side effects arise (Cox et al., 1995; Trotti, 2000).

There are numerous negative effects on oral tissues and oral function resulting from the harmful qualities of such irradiation in the head and neck region. These include infection, hyposalivation, malnutrition, mucositis, mucosal pain and taste disturbance, burning mouth syndrome, fibrosis, trismus, temporomandibular disorders, osteoradionecrosis. Most of the consequences such as taste loss, sore or tender soft tissues, jawbone osteoradionecrosis, fungal infections, mucositis are temporary (Anneroth, 1985; Jham and Freire, 2006; Lieshout and Bots, 2014). Other consequences, such as jaw muscles that have atrophy, trismus, alterations in the proteins and microbiota of bacteria, have a more permanent character (Jham and Freire, 2006; Kielbassa et al., 2006).

Infections may develop during or immediately after radiotherapy. The most common oral infection is candidiasis (Vissink et al., 2003). The most common viral infection is herpes simplex virus infection (Belfield and Dwyer, 2004). Parotid and submandibular salivary glands are affected by radiotherapy. A reduction in salivary production (hyposalivation) and qua-

lity is typically observed as a result of this stimulation (Dirix et al., 2008; Jham and Freire, 2006; Kielbassa et al., 2006). The clinically frequently observed side effect of these changes in the structure of saliva is the rapid deterioration of dental hard tissues (enamel and dentin) (Anneroth, 1985; Jham & Freire, 2006; Kielbassa et al., 2006; Lieshout & Bots, 2014). Patients undergoing radiation therapy will have poor oral function for the remainder of their lives as a result, which will significantly lower their quality of life (Dirix et al., 2008).

Patients receiving radiation therapy to the area of the head and neck may also experience dry mouth if their salivary glands are exposed to significant radiation doses (Likhterov et al., 2018). Dry mouth may last for several months or years or may be permanent for the patient, based on the salivary glands' volume exposed to radiation the overall radiation exposure, and the patient's characteristics (Kuhnt et al., 2005). Furthermore to decreased salivary flow, an increase in salivary viscosity, sodium, chlorine, calcium, magnesium and protein concentrations, but a decrease in pH, bicarbonate concentration and IgA content have been reported (Franzén et al., 1992).

The dietary health of patients receiving radiation therapy to the head and neck region is another aspect that is overlooked or undervalued (Kufeldt et al., 2018). One of the most frequent side effects of radiation therapy to the head and neck region is dysphagia, which is brought on by ailments like the inability to move food from the mouth into the stomach mechanically, a decrease in muscle strength, or a disruption in the coordination of the muscles that control swallowing (Kraaijenga et al., 2015). Etiologic factors of radiotherapy-induced dysphagia include neurotoxicity affecting taste buds, dry mouth, infection, and psychological conditioning (Li et al., 2019).

One of the most frequent side effects of chemotherapy and radiation treatment is mucositis. It is a significant adverse effect of cancer therapy and is characterized by ulceration and inflammation of the oral mucosa. It can also lead to potentially fatal infections. Mucositis, which usually develops in the anterior oral cavity (buccal mucosa, lips and the posterior part of the tongue), is likened to cancer cells by cytotoxic agents due to the rapid division of oral mucosal epithelial cells and is therefore damaged (Rosenthal and Trotti, 2009).

Oral mucositis appears as erythema of the oral mucosa in a patient undergoing a standard 6-7 week radiation treatment in the first two to three weeks of treatment. As the radiation exposure rises, ulceration and pseudo-membranes develop (Sonis et al., 1998). In patients with mucositis, complications such as pain requiring the use of strong analgesics, chewing and

swallowing difficulties, malnutrition, dehydration, anorexia and cachexia are observed; hospitalization periods are prolonged due to infection. Accordingly, the mortality rate increases. Patients may encounter difficulties receiving and finishing treatment regimens as a result of all these issues, particularly if they have an infection (Rosenthal and Trotti, 2009).

Trotti et al. conducted a systematic literature review of 33 studies to assess the incidence and outcomes of oral mucositis in patients receiving radiation therapy for head and neck cancer. Of these studies, 10% reported that the most distressing symptom of oral mucositis was mouth pain (Trotti et al., 2003). Additionally, according to this review, 12% of the studies reported that oral mucositis caused difficulty swallowing, 3% that it caused dehydration, 3% that it caused pain from which opioid-derived analgesics were used, 30% that oral mucositis caused weight loss, and 63% that oral mucositis caused skipping or dose reduction (Trotti et al., 2003).

During active cancer therapy, neurosensory disturbances, mucosal pain that affects diet and quality of life, and taste disturbances are frequent chronic complaints among survivors of cancer (Ganzer et al., 2015). Mucosal discomfort can be linked to dry mouth and possibly subsequent infection. It can also be linked to ulceration, inflammation, mucosal atrophy, or mucosal neuropathy. Radiation-induced neuropathies may result in oxidative stress, inflammation, neurotoxicity, and ischemia (Mukhopadhyay et al., 2023). Neuropathic symptoms might appear at any time during cancer therapy, or they can appear later. Mucosal discomfort is frequently observed during a patient's one-year follow-up and might last long after clinical mucositis has recovered (Epstein et al., 1999).

Secondary "burning mouth syndrome" is the term used to describe persistent or recurring burning mouth brought on by radiation and made worse by xerostomia (McMillan R et al., 2017). Burning or scorching sensations on the tongue, lips, gums, palate, throat, or entire mouth are among the symptoms of burning mouth syndrome. Other symptoms include dry mouth, increased thirst, and taste changes (such as metallic or bitter) (McMillan R et al., 2017).

Mouth pain may be constant or progressively worsen over the course of the day. Years or months may pass throughout it. The symptoms may abruptly go away or infrequently get milder. Consuming food or beverages could offer momentary comfort. In addition to making it difficult to eat and sleep, the discomfort can cause anxiety and sadness. It can be beneficial to abstain from smoke, fizzy drinks, spicy and acidic foods, and high levels of stress (McMillan R et al., 2017).

Treatment of burning mouth syndrome is symptomatic and includes: (McMillan R et al., 2017)

- I. certain mouthwashes for teeth or lidocaine
- II. alternatives for saliva
- III. capsaicin
- IV. clonazepam or klonopin
- V. antidepressants
- VI. analgesic drugs
- VII. low-level laser therapy
- VIII. cognitive behavioral treatment.

One of the latter adverse effects of radiation therapy for head and neck cancer is post-irradiation fibrosis, which can affect several structures in the areas that were exposed to radiation (Sroussi et al., 2017). Damage to the arteries, nerves, and muscles in the neck region can result from radiation exposure. Lymphedema can also result from injury to the lymphatics that remove fluid from the head and neck. Treatment-related fibrosis of the pharyngeal constrictor muscles and tongue muscles can impair swallowing and tongue function. Trismus may result from masticatory muscle fibrosis, primarily in the lateral pterygoids (Sroussi et al., 2017).

Complications from late radiotherapy side effects can include trismus, temporomandibular problems, and fibrosis that impairs lip and tongue function. Radiation therapy to the temporomandibular joint region and the masticatory muscles (masseter, temporalis, medial and lateral pterygoids) results in inflammatory alterations in the muscles that may eventually induce fibrosis (Sroussi et al., 2017).

Difficulties with eating, swallowing, speaking, maintaining basic oral hygiene, wearing dentures, and giving dental care can all be brought on by trismus. According to earlier research, the incidence of radiation-induced trismus in patients with head and neck cancer ranges greatly, from 5% to 45% (Bensadoun et al., 2010).

One new side effect of radiation therapy for head and neck tumors is jaw osteoradionecrosis (de Souza Tolentino et al., 2019). The quick and irreversible death of radioactively irradiated bone is known as osteoradionecrosis (Hancock and Epstein, 2003). It is not a real osteomyelitis; rather, it is the result of inadequate wound healing brought on by radiation therapy's diminished vascularization (Rubenstein et al., 2004). Although the majority of occurrences happen a few years after radiation, osteonecrosis can develop at any point following radiation (Hancock and Epstein, 2003). One of the most dangerous side effects of head and neck radiation therapy is osteoradionecrosis, which is said to occur on its own in one-third of

cases. It is also seen after periodontal and apical diseases, prosthetic applications, surgical procedures, and tooth extraction. At a rate of 2-18%, it has been seen to happen most frequently following tooth extractions carried out following radiation therapy. (Nabil and Samman, 2011). It has been reported that tooth extractions performed immediately before and after radiotherapy are the most common initiating factor causing osteoradionecrosis (Marx and Johnson, 1987). The risk of osteoradionecrosis is twice as high in patients with teeth compared to those without teeth. In addition, the dose, dose rate and application area of radiotherapy also determine the risk of osteonecrosis development (Hancock and Epstein, 2003). Clinical manifestations include discomfort, face fistula, exposing skeletal necrosis, suppuration, and pathological fractures (Hancock and Epstein, 2003; Mossman et al., 1982). Histopathological features include early hyperemia, endarteritis and thrombosis, followed by cell loss, hypovascularity, increasing quantity of bone marrow and fibrosis (Panayiotou et al., 1995).

It is important to remove infected teeth and eliminate infections before treatment. Extraction should be completed three weeks before radiotherapy to prevent necrosis. Systemic antibiotic application has no therapeutic effect since there is bone necrosis. Antibiotics are used only to prevent secondary infections or to treat the infection if it exists (Nabil and Samman, 2011). In most cases, healing occurs within six months with conservative treatment (debridement, antibiotics and saline irrigation). In severe cases that progress despite these treatments, resective surgeries are preferred and can be supported with hyperbaric oxygen treatments (Hancock and Epstein, 2003).

Odontogenesis and similar dental anomalies may occur after radiotherapy. Microdonia, or unusually little teeth, short or blunted roots, small crowns, malocclusion, insufficient calcification, taurodontism, early apical closure, and delayed or stopped tooth development are among the problems that have been reported. When radiation is exposed to odontogenesis during the pre-formation and differentiation phases, the most severe abnormalities are observed (Otmani, 2007).

3.) Radiation Therapy's Impact on Dental Tissues

Dental problems are more common in patients receiving radiation therapy for head and neck malignancies than in other patients. Teeth exposed to radiation exhibit hypovascularity, which results in a reduction in pulpal circulation (Springer et al., 2005). It is believed that radiation therapy directly damages the enamel-dentin junction (Grötz et al., 1998). A notable reduction in enamel's microhardness was noted in case reports with radiation exposure of 20 Gray (Lu et al., 2019). A notable decline in

the microhardness, elasticity modulus, mineral and crystallinity of enamel close to the enamel-dentin junction was observed after radiotherapy (Lu et al., 2019). Similar effects to those of enamel were seen in the decrease in dentin's microhardness at a dose of 20 Gy, and this impact persisted up to 70 Gy. According to a study by Miguel et al., all radiation doses have an impact on the dentin's and enamel's mineral and organic structures, causing their microhardness to drop. This could hasten the development of caries processes (Munoz et al., 2020).

3.1.) Radiation Therapy's Impact on Dental Hard Tissues

Radiation therapy alters dental hard tissues in a substantial way and makes teeth more vulnerable to demineralization (Gupta et al., 2015). Within the first three months following radiation therapy to the head and neck region, the first indications of dental hard tissue degradation are seen (Lieshout and Bots, 2014). After radiotherapy, large porous areas in the enamel, loss of surface enamel, crater formation as a result of exposure of subsurface enamel and exposure of the underlying dentin are frequently observed. This leads to atypical caries formation, is mostly painless and rapid (Kielbassa et al., 2006; Walker et al., 2011). On occasion, the dentin or enamel may appear to be discolored a shade of brown. The cervical and incisal margins are also where this discoloration is primarily found (Vis-sink et al., 2003).

Knychalska et al. examined teeth extracted 6 to 8 months following therapeutic irradiation and found symptoms of significant demineralization, particularly in the structure of the dentin. However, signs of remineralization were also seen in the damaged tissue (Knychalska-Karwan et al., 1988). Shortly after irradiation, substantial damage to the enamel's prismatic structure was seen in another investigation by Grötz et al. (Lieshout and Bots, 2014).

Compared to non-irradiated enamel, the demineralization in irradiated enamel displayed a distinct pattern (Jansma et al., 1993). Significant morphological differences were observed in the demineralization behavior of irradiated enamel (Lieshout and Bots, 2014). It was found that irradiated enamel had greater susceptibility to acid assaults than intact enamel, that its biomechanical characteristics were more significantly impacted, and that dentin's biomechanical characteristics were more significantly diminished (Grötz et al., 1998; Kielbassa et al., 1997).

These findings are contradicted by research on human and bovine teeth conducted *in vitro* and *in situ* by Joyston-Bechal and colleagues. They discovered that neither irradiated nor unirradiated enamel was more prone to demineralization (Joyston-Bechal, 1985; Kielbassa et al., 2006;

Lieshout and Bots, 2014). The same amount of mineral loss and lesion depth were seen (Kielbassa et al., 2006). However, the enamel-dentin junction in irradiated teeth was found to be as scattered, damaged and unstable as the sharply contoured enamel-dentin junction in healthy teeth (Pioch et al., 1992). Dentin's internal stability and the anchoring between it and enamel are both decreased by the radiation-damaged or destroyed biological matrix (Pioch et al., 1992).

Radiation therapy frequently has a negative impact on dentin. In their *in vitro* investigations on the impact of radiation therapy on the dentin of cows, Kielbassa et al. noted a marked reduction in microhardness between dentin that had received radiation and dentin that had not (Kielbassa et al., 2006). Whereas odontoblast activity extends into the enamel in unirradiated teeth, it ceases in advance of the enamel-dentin junction in irradiated teeth (Lieshout and Bots, 2014). Extracted third molars were exposed to radiation up to 31.5 Gy in an *in vitro* investigation by Springer et al., and no appreciable collagen degradation was seen (Springer et al., 2005). All of the tooth's hard structures, including the dentin, enamel-dentin junction, and tooth enamel, exhibit changes. Numerous investigations have demonstrated that these alterations and damages cause these structures' mechanical characteristics to change (Kielbassa et al., 2006; Soares et al., 2010).

Researchers Franzel and colleagues found that after 0.5 Gy of high-energy X-rays used to treat malignancies, there was a substantial deterioration in the mechanical characteristics of dentin and enamel. On the other hand, these enamel characteristics are totally eliminated when therapeutic irradiation starts at a daily dose of 2 Gy (Franzel and Gerlach, 2009).

Walker et al.'s study on the fragility of teeth after radiotherapy showed moderate/severe damage after irradiation in fifty-one percent of teeth. As the irradiation levels increased, a notable rise in damage was seen. Dose-related damage in dental tissues can be classified into 3 stages: 0–30 Gy causes negligible dental damage, Between 30 and 60 Gy, the tooth-dose damage connection doubles or triples, and greater than 60 Gy increases this relationship ten-fold (Walker et al., 2011).

Because saliva includes antibacterial, remineralizing, pH-regulating, and teeth-cleaning properties, it plays a significant role in maintaining the structure of teeth (Dowd, 1999). After radiation therapy, hyposalivation is the primary cause of increased dental caries risk in patients (Escoda-Francoli et al., 2011).

A study by Kielbassa et al. found that saliva pH dropped from 7.0 to 5.0 following radiation therapy, and that this condition exacerbated teeth demineralization tendency. An increase in acidogenic and cariogenic microbes (*Streptococcus mutans*, *Lactobacillus*, and *Candida* species) is seen

in the flora as a result of this alteration in the oral environment. The change in oral flora, the decrease in saliva flow, and the change in saliva composition (buffering capacity, pH, immunoproteins) occur within 3 months from the beginning of radiotherapy, and these changes create a substantial risk of caries and periodontal infections (Gupta et al., 2015).

When the demineralization-remineralization state is out of balance, minerals are lost, damaging the organic phase of the tooth structure and leading to cavitation, which is the production of caries in teeth. Caries that are left untreated advance quickly and may need more extensive care. For this reason, it's critical to identify and stop mineral loss early. It has been discovered that approximately 25% of radiation therapy patients had caries (Michelet, 2012). A parotid-protective application is anticipated to lower the rate of caries because research has demonstrated that the risk of caries in cancer survivors is correlated with the radiation dosage administered to the parotid glands (Hey et al., 2013). Although there is little information on how radiation affects the submandibular gland, it is believed that these glands' activity is crucial for preserving oral health (Lin et al., 2003).

3.2.) Effect of Radiotherapy on Pulp Tissue

The literature on the effects of radiation on dental pulp is not in agreement. Research has indicated that head and neck radiation can stimulate changes in the nervous system and blood vessels in the pulp of the tooth, which can result in pulp necrosis (Weissheimer et al., 2022). At a moderate level of evidence, head and neck radiation generates significant alterations in pulpal response, according to a meta-analysis research assessing the effects of the treatment on pulpal tissues linked with head and neck cancer. Some have stated that because of these inconsistent responses, it is impossible to reliably evaluate the pulpal status of individuals who have had radiation therapy (Weissheimer et al., 2022).

In groups receiving 12 and 18 Gy doses of radiation, head and neck irradiation did not significantly affect inflammation, necrosis, or hyalinization, according to a study by Madani et al. on mice (Madani et al., 2017). There was an acute significant increase in gingival blood flow immediately following radiotherapy, followed by a tendency to return to baseline levels over a prolonged period of time (more than six months), according to another study comparing pulp and gingival blood flow in patients receiving different doses of head and neck radiation immediately after the start of radiotherapy and six months after its completion. High radiation doses (over 50 Gy) had a distinct effect on dental pulp blood flow than did lower radiation doses (below 50 Gy) (Antic et al., 2022). According to a different study examining the direct effects of radiation on the extracellular matrix,

innervation, and microvascularization of the dental pulp in individuals treated with head and neck radiation, radiation did not significantly alter the morphology of these formations (Faria et al., 2014).

Pulse oximetry was used to assess the pulp's vitality in patients with oropharyngeal cancer who received radiation therapy before, during, and six months after the treatment. The results showed that while pulpal oxygenation level (SpO_2) decreased from the start of the treatment to its conclusion (between 60 and 70 Gy), it significantly increased after six months. The significance of waiting six months to a year to assess the pulp's vitality was underlined (Daveshwar et al., 2021). Another study that assessed pulpal sensitivity in patients undergoing head and neck radiation found that patients' sensitivity rose following a 30- to 35-Gy dose (Garg et al., 2015). SpO_2 levels in the pulp were found to be within normal ranges after 4-6 years after radiotherapy, according to a study that assessed the long-term effects of ionizing radiation on pulpal vitality. The authors argued that short-term changes in pulpal microcirculation brought on by radiation might be temporary and that radiation would not have a long-term effect on pulpal vitality. (Kataoka et al., 2016).

In a different study, the impact of head and neck radiation on the immunoexpression of type I collagen, bone morphogenetic protein 4 (BMP4), and bone sialoprotein (BSP) was assessed. Additionally, the study examined whether these changes could facilitate the development and advancement of radiation caries by altering the micromorphology of the dentin-pulp complex. In order to study micromorphology and patterns, demineralized carious tooth sections from head and neck cancer patients (a group of irradiated teeth and a control group of non-irradiated teeth) were examined using traditional optical microscopy and immunohistochemistry. There was no discernible variation in pulp micromorphology across the groups that may be directly related to radiation. Furthermore, there was no difference in the immunohistochemical staining and immunolocalization patterns of type I collagen, BSP, or BMP4 between the irradiated and control samples. This study challenged the concept that head and neck radiotherapy directly destroys the tooth structure by modifying the organic components and microstructure of the pulp, ultimately leading to radiation caries (Fonsêca et al., 2022).

As a result of examining many studies, it has been concluded that although radiotherapy affects pulpal blood flow to some extent in the first 6 months, it does not create a significant difference afterwards, the short-term changes are temporary and it is necessary to wait longer than 6 months to examine pulpal blood flow and pulpal vitality. It has also been thought that radiotherapy affects the pulp differently depending on the dose.

3.3.) Effect of Radiotherapy on Periodontal Tissues

The widespread and chronic microbial/inflammatory illness known as periodontitis is characterized by the destruction of tissues that support teeth, such as the alveolar bone that acts as support for the tooth. Pain, infection of the jaw bones around the roots, and tooth loss are all possible outcomes of periodontitis. Osteoradionecrosis in patients with head and neck cancer may be brought on by periodontitis (Saund et al., 2010).

For many reasons, patients undergoing radiation treatment for head and neck malignancies are more susceptible to periodontal disease than the general population. The primary risk factors for periodontitis are hyposalivation and the loss of saliva's preventive properties. Furthermore, radiation therapy to the head and neck region modifies the flora linked to periodontal disease and alters the oral microbiome (Khaw et al., 2014).

Khaw et al. reported rapid loss of teeth and supporting tissue. Gingival recession and a marked loss of periodontal attachment were observed in patients compared between pre- and post-radiation. Radiotherapy has a dose-dependent effect on periodontal health; as the cumulative dosage increases after the treatment begins, periodontal health deteriorates. Patients with cancer should receive comprehensive information regarding periodontal health because it is linked to an increased risk of osteoradionecrosis and oral mucositis, even in the absence of tooth loss (Khaw et al., 2014).

Radiation therapy is likely to make periodontitis worse because it is a prevalent condition in adults and usually existed prior to the treatment. Furthermore, osteoradionecrosis following tooth extraction may be a consequence of increasing periodontitis, necessitating further dental extractions. It should be remembered that early cancerous tumors might resemble periodontitis, and therefore seeing an oral health specialist can help with the accurate diagnosis (Saund et al., 2010). According to current guidelines, patients should see a dentist before, during, and after cancer treatment who is knowledgeable about the intended treatment for the disease as well as any oral health issues (Hong CHL et al., 2010).

Adult tooth loss is mostly caused by periodontal disease, and teeth with severe periodontitis—especially those in the area that will receive high-dose radiation—may need to be extracted before radiation treatment. Prior to radiation therapy, teeth with lost periodontal attachment and those that will probably need surgery in the future within the scheduled high-dose irradiation fraction should be extracted. In order to reduce the likelihood of increasing periodontitis that requires tooth extraction and the potential consequences of osteoradionecrosis, a lifetime commitment to preventative oral health management is necessary (Hong CHL et al., 2010).

4.) Dental Treatment Planning for Radiotherapy Patients

4.1.) Making Plans for Patients Getting Head and Neck Radiation

Management of oral disease before and during radiation therapy provides various complications for the dentist. Numerous oral side effects of radiation therapy could necessitate changing the dental care plan. Cancers of the salivary glands, lymphomas, and squamous cell carcinoma are among the head and neck diseases that are commonly treated with radiation treatment (Brennan et al., 2008).

Radiation therapy frequently causes mucosal injury or mucositis; therefore, filing down teeth or restorations with sharp edges may lessen the risk of mucosal trauma, the degree of mucositis, and the pain and discomfort that go along with it (Laine et al., 1992). Radiation therapy to the head and neck may raise the incidence of dental cavities and, over time, decrease bone mending capacity. In order to avoid future tooth extractions, which are a major risk factor for post-radiation osteonecrosis, rational restorative dentistry and periodontal therapies, the eradication of dental illness, and the extraction of teeth with doubtful prognosis are all crucial preventive measures. Additionally, fluoride therapy helps reduce radiation-induced caries (Olver et al., 1996 ; Woo et al., 2006).

A number of ideas serve as a guide for treatment planning. These include the risk of bleeding or infection after dental treatments, the risk of osteonecrosis, and the risk of infection during neutropenia. Asking yourself: "If I do not treat this tooth/condition, what is the likelihood of infection developing when the patient has no white cells?" is a crucial question to ask when preparing a chemotherapy treatment. The question for patients who are ready to start IV bisphosphonate therapy or radiation therapy is: How likely is it that this tooth will need to be pulled in the next few years? An crucial question to ask before doing the surgery is: Is this patient at danger for infection or bleeding after the procedure? (Raber-Durlacher et al., 2002). To allow for the shortest possible healing time, it is generally recommended that all decayed teeth be replaced, scaling and prophylaxis done, and extractions done as soon as feasible (Raber-Durlacher et al., 2002). Before receiving cancer therapy, a thorough debridement of plaque and calculus may lower the incidence of oral mucositis and gingivitis (Borowski et al., 1994). When radiation therapy is planned for patients with head and neck cancer, worries about compromised healing should also be taken into account (Vissink et al., 2003). Radiation lowers bone remodeling activity by causing gradual fibrosis and a decrease in cell count (Vissink et al., 2003). Infection and poor recovery can result from invasive dental operations (Pernot et al., 1997). After extractions, patients should aim to

recover for three weeks before beginning radiation therapy (Starcke and Shannon, 1977).

Treatment planning should take the patient's cancer stage and prognosis into account. The dental treatment strategy for a patient with a prognosis of less than six months or for a patient with palliative cancer treatment may comprise dental prophylaxis, uncomplicated restorative dentistry, and extraction of symptomatic teeth with active infection (Epstein et al., 1995).

4.2.) Making Plans for Patients Receiving Head and Neck Radiation Therapy

The dentist's approach to patients who have undergone radiotherapy is to keep complications under control, treat complications that occur, and maintain a healthy condition (Dechaphunkul et al., 2013). Individuals who have had radiation therapy suffer from a severe loss of oral function (such as difficulty chewing food and phonetic abnormalities), which has a detrimental effect on their quality of life (Schweyen et al., 2017). After radiotherapy, there is a decrease in the amount of saliva and an increase in the viscosity of saliva. This negatively affects the patient's oral hygiene. In such cases where oral hygiene decreases, artificial saliva preparations can be used. At the same time, topical fluoride gel application is recommended for these patients to prevent the formation of dental caries. It is recommended that teeth not be extracted for at least six months after radiotherapy. Dental complaints that occur during this period are resolved with conservative treatments. However, if conservative treatments are unsuccessful and the tooth must be extracted; the extraction should be done carefully without damaging the tissues too much and the suture should be placed to cover the alveolar crest. Antibiotics should be given prophylactically before and after the surgical procedure (Engelmeier and King, 1983). If the patient is to receive prosthetic treatment, it is beneficial to wait at least six months. In patients who have extractions immediately before or immediately after radiotherapy, it is recommended to wait one year before starting the prosthesis (Beumer et al., 1996). For orthodontic treatment, this waiting period is two years (Schubert et al., 1998). Studies have revealed that hard and soft tissue atrophy is likely to be noticed after head and neck radiotherapy and that implants may be required. Following radiation therapy, it is advised to wait at least six months, ideally a year, before undergoing implant surgery (Visch et al., 1994).

5.) Effect of Radiotherapy on Dental Treatment

When prosthetic, orthodontic, restorative and endodontic treatments were applied to patients who received radiotherapy, differences were observed in the teeth compared to normal teeth.

5.1.) Effect of Radiotherapy on Restorative Treatment

Teeth restored prior to exposure to gamma radiation performed better in the Gupta et al. trial, which examined the impact of radiotherapy and radiation protection on the efficacy of the self-etch adhesive approach. It has been observed that radiation protection with 0.5 mm lead increases the effectiveness of the self-etch adhesive system irrespective of the radiation exposure stage (Gupta et al., 2022). The radiotherapy protocol had no influence on the marginal adaptation of the universal adhesive in the cervical regions, according to a study by Oğlakçı et al. that looked at the impact of radiation on the marginal adaptation of class II direct resin composite restorations. Compared to etch and rinse application, self-etch adhesive resulted in noticeably more adhesive flaws at the dentin edge when radiation was administered (Oglakci et al., 2022). In their work, Catelan et al. examined the impact of radiation therapy on the radiopacity and flexural strength of composite resin. G1- no irradiation, G2- 30 Gy, G3- 40 Gy, G4- 50 Gy and G5- 60 were formed in 5 groups. The radiopacity values of G1, G3, G5, G4, and G2 were the greatest. G1 has the lowest flexural strength rating, followed by G2, G5, G3, and G4, with no discernible difference between the values. The radiopacity and flexural strength of resin-based composites were unaffected by the widely used radiation treatment dosage (Catelan et al., 2008).

The mechanical behavior of composite resins and adhesive systems was not affected when radiation was applied after the bonding process, but it caused a decrease in the bond strength of adhesive systems when radiation was applied right before the bonding process, according to a study by Troconis et al. that looked at the impact of head and neck radiation on these materials (Madrid et al., 2017). The impact of head and neck radiation on the durability of dental adhesive restorations was the subject of a meta-analysis by Palmier et al., and the results showed that composite resins fared better at two years than both glass ionomer and glass ionomer cements. Glass ionomer cements had a greater failure rate than resin-modified glass ionomer cements, according to the meta-analysis. Comparing composite resins to glass ionomer and glass ionomer cements modified by resin, the former showed a higher failure risk (Palmier et al., 2022).

Gamma radiation treatment was found to considerably diminish the fracture resistance of healthy teeth in the Soares et al. investigation on the

influence of restorative material and gamma irradiation on the biomechanical behavior of root canal filled premolar teeth. It was discovered that teeth treated with amalgam had greater stress than teeth restored with composite resin. It was discovered that the stress values of teeth filled with composite resin were comparable to those of healthy teeth. While increasing the load in the incisal region, gamma irradiation dramatically decreased the fracture resistance. For the restoration of teeth that had undergone endodontic treatment, composite resin outperformed amalgam in terms of biomechanical behavior, regardless of irradiation (Soares et al., 2011).

5.2.) Effect of Radiotherapy on Prosthetic Treatment

Radiotherapy can alter the elastic strength and crystal content of materials based on zirconia, according to a study by Abdullah A. Alshamrani et al. that looked into how ionizing radiation affected the mechanical characteristics and translucency of monolithic zirconia. This phenomenon was more pronounced in low-translucency zirconia (Alshamrani and De Souza, 2020). It was discovered that, regardless of the application method, a radiation dose of 70 Gy impaired the bonding of acrylic resin teeth to acrylic denture bases in the study by Neto et al. on the effect of irradiation on that process (de Moraes et al., 2020).

5.3.) Effect of Radiotherapy on Orthodontic Treatment

The shear strength of ceramic brackets was examined in an *in vitro* study by Neto et al. to investigate the effects of ionizing radiation and various composites. The groups exposed to radiation showed lower shear strength values than the non-exposed groups, but there was no discernible difference between them. It was determined that, independent of the adhesive compound utilized, ionizing radiation adversely damaged the adherence of ceramic brackets (Neto et al., 2022). The physical and adhesive characteristics of tooth enamel following radiotherapy application and the bonding of metal and ceramic brackets were investigated by Santin et al. They discovered that the radiation-exposed enamel portions were weaker than the unirradiated samples. The groups and subgroups that underwent ceramic bracket bonding and radiation exposure were determined to have the lowest strength values. In samples exposed to radiation, a greater rate of bonding failure between the bracket and the composite resin was noted (Santin., 2015).

5.4.) Effect of Radiotherapy on Endodontically Treated Teeth

5.4.1.) Effect of Radiotherapy on Bond Strength in Endodontically Treated Teeth

Yaduka et al. conducted a study whereby two distinct root canal sealers, AH Plus-epoxy resin and BioRoot RCS-bioceramic, were utilized. The study assessed the impact of radiation therapy on the dislocation resistance applied to dentin and the sealer-dentin interface. When compared to non-irradiated teeth, the AH Plus group's irradiated teeth showed noticeably reduced bond strength. In comparison to the AH Plus group, the BioRoot RCS group demonstrated a higher bond strength value following irradiation and did not exhibit a statistically significant drop in bond strength (Yaduka et al., 2021).

The teeth were divided into 5 groups for a different study by Cancelier et al. that looked at the effect of radiation treatment duration on the binding strength between resin cement and dentin. These groups are as follows: Group 1: a control group that did not get radiation treatment, Group 2: radiation received and then root canal treatment, Group 3: irradiated, then root canal preparation and calcium hydroxide placement Group 4: irradiated, then root canal treatment, Group 5: tooth was irradiated and then glass fiber post was applied. The fourth and fifth groups were found to have significantly lower values in the middle third of the obtained values. Radiotherapy had a deleterious effect on the resin cement's adherence to intraradicular dentin in these groups. The group with the best performance was the third one. It was found that the binding between the resin cement and dentin was impacted by the timing of the radiation treatment (Cancelier et al., 2023).

Significantly decreased bond strength values were found after irradiation compared to non-irradiated teeth in the study by Yamin et al. on the endurance of bond strength of resin-based root canal sealers to root dentin following radiation therapy. When compared to the immediate values for irradiated and non-irradiated teeth, the examination conducted after six months showed lower bond strength values. Irradiated dentin developed cohesive problems, and SEM examination revealed fractures, microcracks, and a decrease in collagen fibers in the dentin of the exposed root (Yamin et al., 2018).

According to Lopez et al.'s study, the bond strength between irradiated and non-irradiated teeth was considerably lower for carbodiimide and chlorhexidine resin-based root canal sealers on the bond strength to root dentin following radiation therapy. The groups who received physiological serum and chlorhexidine had irradiation teeth with considerably lower

bond strength values. Furthermore, after ten months, it was shown that these groups' relationship strengths had drastically decreased (Lopes et al., 2020). In teeth exposed to radiation for therapeutic purposes, Martins et al.'s investigation of the impact of epoxy resin or an MTA-containing sealer on the binding strength to root dentin revealed noticeably lower bond strength values in samples filled with MTA Fillapex following irradiation compared to AH Plus. Regardless of the sealer used, radiation has been shown to reduce the bond strength of the sealer to intraradicular dentin and increase the number of gaps that occur at the sealer-dentin interface (Martins et al., 2016).

The impact of radiation on the push-out bond strength of various sealers (Endosequence, MetaSEAL Soft, and Tublseal) to root dentin was assessed in the study carried out by Fouda et al.. Compared to the non-irradiated groups, the irradiated groups showed lower binding strength values. Regardless of radiation exposure and section, the groups filled with Gutta-percha/Tubliseal had the lowest values when comparing sealer. It was discovered that coronal parts had higher bond strength values than mid and apical regions in every group. The root canal dentin binding strength of the sealant was adversely affected by radiotherapy. Compared to MetaSEAL Soft and Tubliseal sealers, Endosequence BC sealer demonstrated a stronger adhesion to radicular dentin (Fouda et al., 2020).

The goal of the Khangwal et al. investigation was to assess how radiation affected the sealer's push-out binding strength to the dentin interface as well as how little the Adseal, MTA Fillapex, and EndoSequence BC sealers adapted to the radioactive dentin. After radiotherapy, bond strength was much lower than in teeth that had not been exposed to radiation. The Adseal root canal sealer exhibited the strongest bond. Dentin adhered to root canal filling material after exposure to radiation, weakening the connection (Khangwal et al., 2022).

Biodentine and mineral trioxide aggregate (MTA) to radicular dentin were shown to have a poorer push-out bond strength to irradiated teeth than to non-irradiated teeth in a study by Khullar et al. that looked at the impact of radiotherapy on these properties. Samples containing non-irradiated Biodentine exhibited the strongest push-out bond strength (Khullar et al., 2023).

5.4.2.) Effect of Radiotherapy on Apical and Coronal Leakage in Endodontically Treated Teeth

There was a modest increase in apical leakage following radiotherapy, but no discernible increase was noted in the study by Bodrumlu et al. that

examined the impact of radiation on the apical sealing of resin-based root canal sealers (Bodrumlu et al., 2009).

Another study by Bodrumlu et al. examined how radiation affected the coronal sealing abilities of two distinct root canal filling materials. While radiation had no effect on either group's ability to seal, it did cause a slight increase in Resilon/Epiphany SE's coronal leakage values (Bodrumlu and Bodrumlu, 2018).

5.4.3.) Effect of Radiotherapy on Apical Periodontitis in Endodontically Treated Teeth

According to Jham et al.'s study, before receiving cancer treatment, people with head and neck cancer typically have severe dental/periodontal illness, poor oral cleanliness, and poor dental care. It is therefore unlikely to infer that the direct effects of radiation on the tooth-bearing areas (independent of the ultimate radiation dosage administered to each tooth) may produce apical periodontitis when assessing patients who did not undergo dental care prior to radiation. This is supported by the fact that the study in question found that teeth with apical periodontitis had a considerably greater caries rate (Jham et al., 2008).

Radiation dose was found to be significantly higher in teeth with apical periodontitis in the Hommez et al. study on the effect of radiation dose on the prevalence of apical periodontitis. Additionally, radiation dose was found to be the only explanatory variable in the presence of apical periodontitis. According to this study, there was a larger chance of developing jaw bone inflammation as a result of bacterial root canal infection in areas with high radiation exposure. This is because radiation therapy altered the bones (Hommez et al., 2012).

However, the same investigators did not discover a higher incidence of apical periodontitis in individuals undergoing head and neck radiation in a prior investigation. Therefore, it was believed that these interpretations would support the notion that teeth are immediately destroyed by radiation, which might mislead general practitioners to eventually refrain from treating patients following radiation therapy. Finally, it should not be assumed that radiation therapy directly affected teeth and the jawbone because apical periodontitis is a very common oral finding in the community both before and after head and neck radiation (Hommez et al., 2012).

5.4.4.) Effect of Radiotherapy on Fracture Strength of Endodontically Treated Teeth

It has been asserted that the application and duration of radiotherapy affect the fracture strength of teeth receiving root canal treatments and lowers fracture strength values. Türker et al. looked into the impact of radiation application time on fracture strength in teeth filled with biodentin or gutta percha/root canal sealer. For six weeks, the teeth in the trial received 60 Gy and 2 Gy dosages every day, five days a week. There were 72 teeth in all, 24 of which were used as the control group. The 48 teeth that were left were split into 4 groups, 2 of which had radiotherapy before to root canal therapy and the other 2 groups had radiotherapy following root canal therapy.

The teeth that underwent radiotherapy after receiving a biodentin root canal filling had the lowest fracture strength values, whereas the group that did not receive radiotherapy had the highest values. It was discovered that the amount of radiation applied to teeth filled with gutta percha and root canal sealant was negligible. When biodentin was used for filling, it was discovered that the radiation dosage was substantial. When compared to teeth filled with gutta-percha and root canal sealer, either before or after radiotherapy, the fracture strength value of teeth treated with radiotherapy following biodentin filling was shown to be considerably lower (Aktemur Türker et al., 2021).

Radiation therapy was found to dramatically lower the fracture strength of healthy teeth in the Soares et al. study, which looked at the impact of gamma irradiation and restorative material on the biomechanical behavior of root canal-treated premolar teeth (Soares et al., 2011). The impact of therapeutic radiation doses on the fracture strength of teeth filled with gutta-percha and two sealers after root canal therapy was examined in the study by Omaia et al.. Following irradiation, all groups showed a significant drop in fracture strength; the CeraSeal root canal sealer showed the least decrease in fracture strength. CeraSeal outperformed Adseal in the fracture strength values of the tooth following irradiation (Omaia et al., 2024). It is possible to argue that the material used in root canal fillings affects the teeth's ability to withstand fracture for the reasons mentioned above.

5.4.5.) Effect of Radiotherapy on Biomechanical Behavior of Endodontically Treated Teeth

According to a study by Novais et al., radiation therapy negatively affects the microhardness of dentin in both humans and cattle, and this effect gets worse after endodontic treatments. The mechanical characteristics of

irradiation dentin are adversely affected by endodontic treatment as well; restorative methods should take this effect into consideration (Novais et al., 2016).

The study by Pauletto et al. examined how radiation and a taper of root canal preparation affected the mesial roots of mandibular molars' biomechanical behavior. Fatigue strength reduced as the taper of the preparation increased. The biomechanical performance was considerably affected by radiotherapy. When exposed to radiation and when the preparation's taper grew, the biomechanical behavior of the mandibular molars' mesial roots dramatically reduced (Pauletto et al., 2024).

BİBLİOGRAPHY

- Akkaş, E. A. , Yücel, B., Kılıçkap, S., Babacan, N. A. & Elif, E. (2013). Orijinal araştırma-Original research Baş boyun kanserli hastalarda tedavi sonuçları ve prognostik faktörler Results and prognostic factors in patients with head and neck cancer. *Cumhuriyet Medical Journal*, 35(1), 66-75. <https://doi.org/10.7197/1305-0028.1744>
- Aktemur Türker, S., Kaşıkçı, S., Uzunoğlu Özyürek, E., Olcay, K. & Elmas, Ö. (2021). The effect of radiotherapy delivery time and obturation materials on the fracture resistance of mandibular premolars. *Clin Oral Investig.* 25(3):901-905. doi:10.1007/s00784-020-03378-2
- Alshamrani, A. A., & De Souza, G. M. (2020). Effect of ionizing radiation on mechanical properties and translucency of monolithic zirconia. *Journal of biomedical materials research. Part B, Applied Biomaterials*, 108(3), 1068–1076. <https://doi.org/10.1002/JBM.B.34458>
- Anneroth, G. (1985). The effect of radiation on teeth: A clinical, histologic and microradiographic study. *International Journal of Oral Surgery*, 14(3), 269–274. [https://doi.org/10.1016/S0300-9785\(85\)80038-7](https://doi.org/10.1016/S0300-9785(85)80038-7)
- Antic, S., Markovic-Vasiljkovic, B., Dzeletovic, B., Jelovac, D. B., & Kuzmanovic-Pficer J. (2022). Assesment of radiotherapy effects on the blood flow in gingiva and dental pulp - a laser Doppler flowmetry study. *Journal of Applied Oral Science*, 30:e20220329. doi: 10.1590/1678-7
- Ballas, R. K., Shah, A. A. (2011). Fundamentals of Patient Management. In :Perez CA, Brady LW. Radiation Oncology Management Decisions, Third Ed. Philadelphia, Lippincott Williams & Wilkins. 1-12
- Belfield, P. M., & Dwyer, A. A. (2004). Oral complications of childhood cancer and its treatment: current best practice. *European Journal of Cancer*, 40(7), 1035-1041. doi: 10.1016/j.ejca.2003.09.041
- Beumer III J, Curtis TA, Marunick MT. Beumer J. (1996). Maxillofacial rehabilitation: prosthodontic and surgical considerations. St Louis: Ishiyaku Euro-America, Inc.: 240-285
- Bodrumlu, E., Avsar, A., Meydan, A. D., & Tuloglu, N. (2009). Can radiotherapy affect the apical sealing ability of resin-based root canal sealers?. *The Journal of the American Dental Association*, 140(3), 326-330. <https://doi.org/10.14219/jada.archive.2009.0162>
- Bodrumlu, E. H., & Bodrumlu, E. (2018). Effect of radiotherapy on the coronal-sealing ability of two different root canal sealing materials. *Nigerian Journal of Clinical Practice*, 21(8), 1008-1011. https://doi.org/10.4103/njcp.njcp_377_1
- Borowski, B., Benhamou, E., Pico, J. L., Laplanche, A., Margainaud, J. P., & Hayat, M. (1994). Prevention of oral mucositis in patients treated with high-dose chemotherapy and bone marrow transplantation: a randomised controlled trial comparing two protocols of dental care. *European journal of can-*

- cer. Part B, Oral oncology, 30B(2), 93–97. [https://doi.org/10.1016/0964-1955\(94\)90059-0](https://doi.org/10.1016/0964-1955(94)90059-0)
- Bourland, J. D. (2012). Radiation oncology physics. In: Gunderson LL, Tepper JS, Editors. Clinical radiation oncology. 3rd Ed. Philadelphia, Saunders. 95-152 73
- Bray, F., Ferlay, J., Soerjomataram, I., Siegel, R. L., Torre, L. A., & Jemal, A. (2018). Global cancer statistics 2018: GLOBOCAN estimates of incidence and mortality worldwide for 36 cancers in 185 countries. *CA: A Cancer Journal For Clinicians*, 68(6), 394-424
- Brennan, M. T., Woo, S. B., & Lockhart, P. B. (2008). Dental treatment planning and management in the patient who has cancer. *Dental clinics of North America*, 52(1), 19–vii. <https://doi.org/10.1016/j.cden.2007.10.003>
- Cancelier, P. D. A., Machado, R. G., Savaris, J. M., Bortoluzzi, E. A., Teixeira, C. D. S., Minamisako, M. C., Rodrigues, P. M., Netto, V. R., Dutra-Horstmann, K. L., & Garcia, L. D. F. R. (2023). Effect of the timing of radiation therapy on the push-out strength of resin cement to root dentine. *Australian endodontic journal : the journal of the Australian Society of Endodontology Inc*, 49 Suppl 1, 122–131. <https://doi.org/10.1111/aej.12699>
- Catelan, A., Padilha, A. C., Salzedas, L. M., Coclete, G. A., dos Santos, P. H. (2008). Effect of radiotherapy on the radiopacity and flexural strength of a composite resin. *Acta Odontol Latinoam*, 21(2), 159-162.
- Cohen, N., Fedewa, S., & Chen, A.Y. (2018). Epidemiology and demographics of the head and neck cancer population, *Oral and Maxillofacial Surgery Clinics*, 30(4), 381-395. (y.y.). 30(4), 381-395
- Cox, J.D., Stetz, J., Pajak, T. F. (1995). Toxicity criteria of the radiation therapy oncology group (RTOG) and the European organization for research and treatment of cancer (EORTC). *International Journal of Radiation Oncology*, 31(5), 1341-6
- Çitlak, K., & Kapucu, S. (2017). Kemoterapi ve radyoterapi uygulanan baş-boyun kanserli hastalarda mukozit yönetimine yönelik kullanılan oral ajanların retrospektif olarak incelenmesi. *Hacettepe Üniversitesi Hemşirelik Fakültesi Dergisi*, 4(1), 15-27
- Daveshwar, S. R., Kapoor, S. V., & Daveshwar, M. R. (2021). A clinical study determining pulp vitality in oropharyngeal cancer patients undergoing radiotherapy using diagnostic tool-pulse oximetry. *Current Health Sciences Journal*, 47(1), 5. doi:10.12865/CHSJ.47.01.01
- De Souza Tolentino, E., de Castro, T. F., Michellon, F. C., Passoni, A. C. C., Ortega, L. J. A., & Iwaki L. C. V. (2019). Adjuvant therapies in the management of medication-related osteonecrosis of the jaws: Systematic review. *Head Neck*. 41(12), 4209-28
- Dechaphunkul, T., Martin, L., Alberda, C., Olson, K., Baracos, V., & Gramlich, L. (2013). Malnutrition assessment in patients with cancers of the head and

- neck: a call to action and consensus. *Critical reviews in oncology/hematology*, 88(2), 459–476. <https://doi.org/10.1016/j.critrevonc.2013.06.003>
- de Moraes Melo Neto, C. L., da Silva Dantas, L. A., AC, P. M., da Silva, M. A., JOH, R. F., Santin, G. C., & Sábio, S. (2020). Effect of radiotherapy on the artificial acrylic resin tooth bond to the acrylic resin denture base. *General Dentistry*, 68(2), 66-69.
- Delaney, G., Jacob, S., Featherstone, C., & Barton, M. (2005). The role of radiotherapy in cancer treatment. *Cancer*, 104(6):1129-1137. doi:10.1002/CNCR.21324
- Dirix, P., Nuyts, S., Vander Poorten, V., Delaere, P., & Van den Bogaert, W. (2008). The influence of xerostomia after radiotherapy on quality of life: results of a questionnaire in head and neck cancer. *Supportive Care in Cancer*, 16, 171-179. doi: 10.1007/s00520-007-030
- Dowd F. J. (1999). Saliva and dental caries. *Dental clinics of North America*, 43(4), 579–597
- Dreizen, S., Daly, T. E., Drane, J. B., & Brown, L. R. (1977). Oral complications of cancer radiotherapy. *Postgraduate Medicine*, 61(2), 85-92
- Engelmeier, R. L., & King, G. E. (1983). Complications of head and neck radiation therapy and their management. *The Journal of prosthetic dentistry*, 49(4), 514–522. [https://doi.org/10.1016/0022-3913\(83\)90314-1](https://doi.org/10.1016/0022-3913(83)90314-1)
- Engin, K., & Erişen, L. (2003). Baş-boyun kanserleri. *İstanbul, Nobel Tıp Kitabevi*, 920- 934.
- Epstein, J. B., van der Meij, E. H., Emerton, S. M., Le, N. D., & Stevenson-Moore, P. (1995). Compliance with fluoride gel use in irradiated patients. *Special care in dentistry : official publication of the American Association of Hospital Dentists, the Academy of Dentistry for the Handicapped, and the American Society for Geriatric Dentistry*, 15(6), 218–222. <https://doi.org/10.1111/j.1754-4505.1995.tb00521.x>
- Epstein, J. B., Emerton, S., Kolbinson, D. A., Le, N. D., Phillips, N., Stevenson-Moore, P., & Osoba, D. (1999). Quality of life and oral function following radiotherapy for head and neck cancer. *Head & neck*, 21(1), 1–11. [https://doi.org/10.1002/\(sici\)1097-0347\(199901\)21:1<1::aid-hed1>3.0.co;2-4](https://doi.org/10.1002/(sici)1097-0347(199901)21:1<1::aid-hed1>3.0.co;2-4)
- Ertem, G., & Kalkım. (2009). Radyoterapi alan hastaların evde bakım gereksinimleri ve yaşam kaliteleri. *Maltepe Üniversitesi Hemşirelik Bilim ve Sanatı Dergisi*, 2(2): 4-12
- Escoda-Francolí, J., Rodríguez-Rodríguez, A., Pérez-García, S., Gargallo-Albiol, J., & Gay-Escoda, C. (2011). Dental implications in oral cancer patients. *Medicina Oral, Patología Oral Y Cirugía Bucal*, 16(4), e508–e513. <https://doi.org/10.4317/medoral.16.e508>

- Faria, K. M., Brandão, T. B., Ribeiro, A. C., Vasconcellos, A. F., de Carvalho, I. T., de Arruda, F. F., Castro Junior, G., Gross, V. C., Almeida, O. P., Lopes, M. A., & Santos-Silva, A. R. (2014). Micromorphology of the dental pulp is highly preserved in cancer patients who underwent head and neck radiotherapy. *Journal of Endodontics*, 40(10), 1553–1559. <https://doi.org/10.1016/j.joen.2014.07.006>
- Fonsêca, J. M., Martins, M. D., Vargas, P. A., Silva, W. G., Normando, A. G. C., Palmier, N. R., Ribeiro, A. C. P., Brandão, T. B., Lopes, M. A., Goes, M. F., & Santos-Silva, A. R. (2022). Preservation of immunoexpression of type I collagen, BSP and BMP4 in the dentin-pulp complex of head and neck cancer patients after radiotherapy. *Brazilian Oral Research*, 36, e012. <https://doi.org/10.1590/1807-3107bor-2022.vol36.0012>
- Fränzel, W., & Gerlach, R. (2009). The irradiation action on human dental tissue by X-rays and electrons--a nanoindenter study. *Zeitschrift für medizinische Physik*, 19(1), 5–10. <https://doi.org/10.1016/j.zemedi.2008.10.009>
- Franzén, L., Funegård, U., Ericson, T., & Henriksson, R. (1992). Parotid gland function during and following radiotherapy of malignancies in the head and neck: A consecutive study of salivary flow and patient discomfort. *European Journal of Cancer*, 28(2–3), 457–462. [https://doi.org/10.1016/S0959-8049\(05\)80076-0](https://doi.org/10.1016/S0959-8049(05)80076-0)
- Fouda, S. A., Labib, A. H., Shaheen, N. A., Abd-Elbary, N. M., & Alhadainy, H. A. (2020). Effect of radiotherapy on bond strength of different endodontic sealers to root dentin. *Tanta Dental Journal*, 17(3), 85-89.
- Ganzer, H., Touger-Decker, R., Byham-Gray, L., Murphy, B. A., & Epstein, J. B. (2015). The eating experience after treatment for head and neck cancer: A review of the literature. *Oral oncology*, 51(7), 634–642. <https://doi.org/10.1016/j.oraloncology.2015.04.014>
- Garg, H., Grewal, M. S., Rawat, S., Suhag, A., Sood, P. B., Grewal, S., & Ahlawat, P. (2015). Dental Pulp Status of Posterior Teeth in Patients with Oral and Oropharyngeal Cancer Treated with Concurrent Chemoradiotherapy. *Journal Of Endodontics*, 41(11), 1830–1833. <https://doi.org/10.1016/j.joen.2015.08.006>
- Gemici, C., Mayadağlı, A., & Parlak, C. (2004). Radyasyon Onkolojisi Tedavi Kararları. *İstanbul, Nobel Tıp Kitapevi*, 706-803
- Grötz, K. A., Duschner, H., Kutzner, J., Thelen, M., & Wagner, W. (1998). Histotomographic study of the direct effects of radiation on dental enamel. *Mund-, Kiefer-und Gesichtschirurgie*, 2, 85-90
- Grubbé, E. H. (1933). Priority in the therapeutic use of X-rays. *Radiology*, 21(2), 156-162. doi:10.1148/21.2.156
- Gupta, N., Pal, M., Rawat, S., Grewal, M.S., Garg, H., Chauhan, D., Ahlawat, P., Tandon, S., Khurana, R., Pahuja, A.K., Mayank, M., & Devnani, B. (2015).

Radition-induced dental caries, prevention and treatment- A systematic review. *National Journal of Maxillofacial Surgery*, 6(2), 160–166

Gupta, S., Bogra, P., Sharma, D., Goyal, R., Dhir, S., & Gupta, B. (2022). Impact of radiotherapy and shielding on the efficacy of the self-etch adhesive technique. *Journal of Conservative Dentistry and Endodontics*, 25(4):444-447. https://doi.org/10.4103/jcd.jcd_238_22

Haefner, M. F., Lang, K., Krug, D., Koerber, S. A., Uhlmann, L., Kieser, M., Debus, J., & Sterzing, F. (2015). Prognostic factors, patterns of recurrence and toxicity for patients with esophageal cancer undergoing definitive radiotherapy or chemo-radiotherapy. *Journal of Radiation Research*, 56(4), 742–749. <https://doi.org/10.1093/jrr/rrv022>

Hancock, P. J., Epstein, J. B., & Sadler, G. R. (2003). Oral and dental management related to radiation therapy for head and neck cancer. *Journal (Canadian Dental Association)*, 69(9), 585–590

Hey, J., Seidel, J., Schweyen, R., Paelecke-Habermann, Y., Vordermark, D., Gernhardt, C., & Kuhnt, T. (2013). The influence of parotid gland sparing on radiation damages of dental hard tissues. *Clinical oral investigations*, 17(6), 1619–1625. <https://doi.org/10.1007/s00784-012-0854-6>

Hommez G, De Meerleer G, Vakaet L, De Neve W, Vermeersch H, De Moor R. (2008). Prevalence of apical periodontitis and associated coronal factors in head and neck irradiated patients. *Endod Pract Today* 2:105–116

Hommez, G. M., De Meerleer, G. O., De Neve, W. J., & De Moor, R. J. (2012). Effect of radiation dose on the prevalence of apical periodontitis—a dosimetric analysis. *Clinical Oral Investigations*, 16(6), 1543–1547. <https://doi.org/10.1007/s00784-011-0665-1>

Hong, C. H., Napeñas, J. J., Hodgson, B. D., Stokman, M. A., Mathers-Stauffer, V., Elting, L. S., Spijkervet, F. K., Brennan, M. T. (2010). Dental Disease Section, Oral Care Study Group, Multi-national Association of Supportive Care in Cancer (MASCC)/International Society of Oral Oncology (ISOO). A systematic review of dental disease in patients undergoing cancer therapy. *Supportive care in cancer : official journal of the Multinational Association of Supportive Care in Cancer*, 18(8), 1007–1021. <https://doi.org/10.1007/s00520-010-0873-2>

Jansma, J., Vissink, A., Jongebloed, W. L., Retief, D. H., & Johannes 's-Gravenmade, E. (1993). Natural and induced radiation caries: A SEM study. *American journal of dentistry*, 6(3), 130–136

Jham, B. C., & da Silva Freire, A. R. (2006). Oral complications of radiotherapy in the head and neck. *Brazilian Journal of Otorhinolaryngology*, 72(5), 704–708. [https://doi.org/10.1016/s1808-8694\(15\)31029-6](https://doi.org/10.1016/s1808-8694(15)31029-6)

Jham BC, Reis PM, Miranda EL, Lopes RC, Carvalho AL, Scheper MA, Freire AR (2008) Oral health status of 207 head and neck cancer patients before, during and after radiotherapy. *Clin Oral Investig* 12:19–24

- Joyston-Bechal S. (1985). The effect of X-radiation on the susceptibility of enamel to an artificial caries-like attack in vitro. *Journal of Dentistry*, 13(1), 41–44. [https://doi.org/10.1016/0300-5712\(85\)90061-2](https://doi.org/10.1016/0300-5712(85)90061-2)
- Kamangar, F., Dores, G. M., & Anderson, W. F. (2006). Patterns of cancer incidence, mortality, and prevalence across five continents: defining priorities to reduce cancer disparities in different geographic regions of the world. *Journal of Clinical Oncology : Official Journal of the American Society of Clinical Oncology*, 24(14), 2137–2150. <https://doi.org/10.1200/JCO.2005.05.2308>
- Karthikeyan, G., Jumrani, D., Prabhu, R., Manoor, U. K., & Supe, S. S. (2012). Prevalence of fatigue among cancer patients receiving various anticancer therapies and its impact on quality of life: a cross-sectional study. *Indian Journal of Palliative Care*, 18(3), 165–175. <https://doi.org/10.4103/0973-1075.105686>
- Kataoka, S. H., Setzer, F. C., Gondim-Junior, E., Fregnani, E. R., Moraes, C. J., Pessoa, O. F., Gavini, G., & Caldeira, C. L. (2016). Late effects of head and neck radiotherapy on pulp vitality assessed by pulse oximetry. *Journal of Endodontics*, 42(6), 886–889. <https://doi.org/10.1016/j.joen.2016.02.016>
- Khangwal, M., Solanki, R., & Rahman, H. (2022). Effect of therapeutic fractionated radiotherapy on bond strength and interfacial marginal adaptation of Adseal, MTA Fillapex, and EndoSequence BC sealer: An: in vitro: study. *Saudi Endodontic Journal*, 12(3), 289–296.
- Khaw, A., Logan, R., Keefe, D., & Bartold, M. (2014). Radiation-induced oral mucositis and periodontitis - proposal for an inter-relationship. *Oral Diseases*, 20(3), e7–e18. <https://doi.org/10.1111/odi.12199>
- Khullar, L., Ballal, N. V., Eyüboğlu, T. F., & Özcan, M. (2023). Does radiation therapy affect adhesion of tricalcium silicate cements to root dentin?. *Journal of Applied Oral Science*, 31, e20230118.
- Kielbassa, A. M., Beetz, I., Schendera, A., & Hellwig, E. (1997). Irradiation effects on microhardness of fluoridated and non-fluoridated bovine dentin. *European Journal of Oral Sciences*, 105(5 Pt 1), 444–447. <https://doi.org/10.1111/j.1600-0722.1997.tb02142.x>
- Kielbassa, A. M., Hinkelbein, W., Hellwig, E., & Meyer-Lückel, H. (2006). Radiation-related damage to dentition. *The Lancet. Oncology*, 7(4), 326–335. [https://doi.org/10.1016/S1470-2045\(06\)70658-1](https://doi.org/10.1016/S1470-2045(06)70658-1)
- Knychalska-Karwan, Z., Pawlicki, R., & Karwan, T. (1988). Structural and microanalytical changes in dentition after radiotherapy applied in cases of tumour in the oral cavity region. *Folia Histochemica Et Cytobiologica*, 26(1), 25–32
- Kraaijenga, S. A., van der Molen, L., Jacobi, I., Hamming-Vrieze, O., Hilgers, F. J., & van den Brekel, M. W. (2015). Prospective clinical study on long-term swallowing function and voice quality in advanced head and neck

cancer patients treated with concurrent chemoradiotherapy and preventive swallowing exercises. *European archives of oto-rhino-laryngology : official journal of the European Federation of Oto-Rhino-Laryngological Societies (EUFOS) : Affiliated With the German Society for Oto-Rhino-Laryngology - Head and Neck Surgery*, 272(11), 3521–3531. <https://doi.org/10.1007/s00405-014-3379-6>

- Kufeldt, J., Viehrig, M., Schweikert, D., Fritsche, A., Bamberg, M., & Adolph, M. (2018). Treatment of malnutrition decreases complication rates and shortens the length of hospital stays in a radiation oncology department. *Clinical Nutrition*, 194(11), 1049–1059. <https://doi.org/10.1007/s00066-018-1360-9>
- Kuhnt, T., Jirsak, N., Müller, A. C., Pelz, T., Gernhardt, C., Schaller, H.-G., Janich, M., Gerlach, R., & Dunst, J. (2005). Strahlentherapie und Onkologie Quantitative und qualitative Speicheldrüsenfunktions-untersuchungen in Abhängigkeit von Dosis und Volumen einer Radiotherapie zur Verringerung der Xerostomie bei Kopf-Hals-Tumoren Quantitative and Qualitative Investigations of Salivary Gland Function in Dependence on Irradiation Dose and Volume for Reduction of Xerostomia in Patients with Head-and-Neck Cancer. *Strahlenther Onkol*, 8. <https://doi.org/10.1007/s00066-005-1366-y>
- Kumar, V., Abbas, A.K. & Aster, J.C. (2017). *Robbins Basic Pathology*. E-Book, Elsevier Health Sciences, Amsterdam, 57-97
- Laine, P. O., Lindqvist, J. C., Pyrhönen, S. O., Strand-Pettinen, I. M., Teerenhovi, L. M., & Meurman, J. H. (1992). Oral infection as a reason for febrile episodes in lymphoma patients receiving cytostatic drugs. *European journal of cancer. Part B, Oral oncology*, 28B(2), 103–107. [https://doi.org/10.1016/0964-1955\(92\)90036-z](https://doi.org/10.1016/0964-1955(92)90036-z)
- Li, H., Li, L., Huang, X., Li, Y., Zou, T., Zhuo, X., Chen, Y., Liu, Y., & Tang, Y. (2019). Radiotherapy-induced dysphagia and its impact on quality of life in patients with nasopharyngeal carcinoma. *Strahlentherapie und Onkologie*, 195(6), 457-467. <https://doi.org/10.1007/s00066-018-01421-6>
- Lieshout, H. F., & Bots, C. P. (2014). The effect of radiotherapy on dental hard tissue--a systematic review. *Clinical Oral Investigations*, 18(1), 17–24. <https://doi.org/10.1007/s00784-013-1034-z>
- Likhterov, I., Ru, M., Ganz, C., Urken, M. L., Chai, R., Okay, D., Liu, J., Stewart, R., Culliney, B., Palacios, D., & Lazarus, C. L. (2018). Objective and subjective hyposalivation after treatment for head and neck cancer: Long-term outcomes. *The Laryngoscope*, 128(12), 2732–2739. <https://doi.org/10.1002/lary.27224>
- Lin, A., Kim, H. M., Terrell, J. E., Dawson, L. A., Ship, J. A., & Eisbruch, A. (2003). Quality of life after parotid-sparing IMRT for head-and-neck cancer: a prospective longitudinal study. *International journal of radiation oncology, biology, physics*, 57(1), 61–70. [https://doi.org/10.1016/s0360-3016\(03\)00361-4](https://doi.org/10.1016/s0360-3016(03)00361-4)

- Lopes, F. C., Roperto, R., Akkus, A., de Queiroz, A. M., Francisco de Oliveira, H., & Sousa-Neto, M. D. (2020). Effect of carbodiimide and chlorhexidine on the bond strength longevity of resin cement to root dentine after radiation therapy. *International Endodontic Journal*, 53(4), 539–552. <https://doi.org/10.1111/iej.13252>
- Lu, H., Zhao, Q., Guo, J., Zeng, B., Yu, X., Yu, D., & Zhao, W. (2019). Direct radiation-induced effects on dental hard tissue. *Radiation oncology (London, England)*, 14(1), 5. <https://doi.org/10.1186/s13014-019-1208-1>
- Madani, Z. S., Azarakhsh, S., Shakib, P. A., & Karimi, M. (2017). Histopathological changes in dental pulp of rats following radiotherapy. *Dental Research Journal*, 14(1), 19–24. <https://doi.org/10.4103/1735-3327.201139>
- Madrid, C. C., de Pauli Paglioni, M., Line, S. R., Vasconcelos, K. G., Brandão, T. B., Lopes, M. A., Santos-Silva, A. R., & De Goes, M. F. (2017). Structural Analysis of Enamel in Teeth from Head-and-Neck Cancer Patients Who Underwent Radiotherapy. *Caries Research*, 51(2), 119–128. <https://doi.org/10.1159/000452866>
- Martins, C. V., Leoni, G. B., Oliveira, H. F., Arid, J., Queiroz, A. M., Silva, L. A., & Sousa-Neto, M. D. (2016). Influence of therapeutic cancer radiation on the bond strength of an epoxy- or an MTA-based sealer to root dentine. *International Endodontic Journal*, 49(11), 1065–1072. <https://doi.org/10.1111/iej.12556>
- Marx, R. E., & Johnson, R. P. (1987). Studies in the radiobiology of osteoradionecrosis and their clinical significance. *Oral surgery, oral medicine, and oral pathology*, 64(4), 379–390. [https://doi.org/10.1016/0030-4220\(87\)90136-8](https://doi.org/10.1016/0030-4220(87)90136-8)
- McMillan, R., Forssell, H., Ja, B., Am, G., & Jc W, Zakrzewska Jm. (2017). Little evidence to support or refute interventions for the management of burning mouth syndrome. *Evidence-Based Dentistry*, 2017;18(2):57-58. doi:10.1038/sj.ebd.6401244.
- Michelet M. (2012). Caries and periodontal disease in cancer survivors. *Evidence-based dentistry*, 13(3), 70–73. <https://doi.org/10.1038/sj.ebd.6400870>
- Moss, W. T., & Cox, J. D. (1994). *Moss' radiation oncology : rationale, technique, results (7th ed.)*. Mosby.
- Mossman, K., Shatzman, A., & Chencharick, J. (1982). Long-term effects of radiotherapy on taste and salivary function in man. *International journal of radiation oncology, biology, physics*, 8(6), 991–997. [https://doi.org/10.1016/0360-3016\(82\)90166-3](https://doi.org/10.1016/0360-3016(82)90166-3)
- Mukhopadhyay, S., Sen, S., Ghosh, P., Gehani, A., Patra, A., Chandra, A., ... & Khoda, J. (2023). Imaging Recommendations for Diagnosis, Staging and Management of Treatment-Related Complications in Cancer. *Indian Journal of Medical and Paediatric Oncology*, 44(03), 322-333.
- Muñoz, M. A., Garín-Correa, C., González-Arriagada, W., Quintela Davila, X., Häberle, P., Bedran-Russo, A., & Luque-Martínez, I. (2020). The adverse

effects of radiotherapy on the structure of dental hard tissues and longevity of dental restoration. *International Journal of Radiation Biology*, 96(7), 910–918. <https://doi.org/10.1080/09553002.2020.1741718>

- Nabil, S., & Samman, N. (2011). Incidence and prevention of osteoradionecrosis after dental extraction in irradiated patients: a systematic review. *International Journal of Oral and Maxillofacial Surgery*, 40(3), 229–243. <https://doi.org/10.1016/j.ijom.2010.10.005>
- Neto, A., Amaral, F., & Romano, F. (2022). Effects of ionizing radiation and different resin composites on shear strength of ceramic brackets: an in vitro study. *Dental Press Journal Of Orthodontics*, 27(2), e2219330. <https://doi.org/10.1590/2177-6709.27.2.e2219330.oar>
- Novais, V. R., Soares, P. B. F., Guimarães, C. M., Schliebe, L. R. S. O., Braga, S. S. L., & Soares, C. J. (2016). Effect of gamma radiation and endodontic treatment on mechanical properties of human and bovine root dentin. *Brazilian dental journal*, 27, 670-674.
- Oglakci, B., Burduroğlu, D., Eriş, A. H., Mayadağlı, A., & Arhun, N. (2022). The effect of radiotherapy on the marginal adaptation of class II direct resin composite restorations: a micro-computed tomography analysis. *Operative Dentistry*, 47(1), 43–54. <https://doi.org/10.2341/20-066-L>
- Olver, I. N., Hughes, P. G., Smith, J. G., Narayan, K., & Bishop, J. F. (1996). Concurrent radiotherapy and continuous ambulatory infusion 5-fluorouracil in advanced head and neck cancer. *European journal of cancer (Oxford, England : 1990)*, 32A(2), 249–254. [https://doi.org/10.1016/0959-8049\(95\)00539-0](https://doi.org/10.1016/0959-8049(95)00539-0)
- Omaia, M., Abaza, E., & Abdelbaky, M. (2024). The effect of therapeutic dose of gamma radiation on fracture resistance of endodontically treated tooth obturated using different types of sealers (An in-vitro study). *Egyptian Dental Journal*, 70(3), 2767-2773.
- Otmani N. (2007). Oral and maxillofacial side effects of radiation therapy on children. *Journal (Canadian Dental Association)*, 73(3), 257–261.
- Özalpan, A. (2001). *Temel Radyobiyojoloji*. 1. Basım. İstanbul: Haliç Üniversitesi Yayınları, 1-218.
- Palmier, N. R., Madrid Troconis, C. C., Normando, A. G. C., Guerra, E. N. S., Araújo, A. L. D., Arboleda, L. P. A., Fonsêca, J. M., de Pauli Paglioni, M., Gomes-Silva, W., Vechiato Filho, A. J., González-Arriagada, W. A., Paes Leme, A. F., Prado-Ribeiro, A. C., Brandão, T. B., de Goes, M. F., Lopes, M. A., & Santos-Silva, A. R. (2022). Impact of head and neck radiotherapy on the longevity of dental adhesive restorations: A systematic review and meta-analysis. *The Journal of Prosthetic Dentistry*, 128(5), 886–896. <https://doi.org/10.1016/J.PROSDENT.2021.02.002>
- Panayiotou, H., Small, S. C., Hunter, J. H., & Culpepper, R. M. (1995). Sweet taste (dysgeusia). The first symptom of hyponatremia in small cell carcinoma of

- the lung. *Archives of internal medicine*, 155(12), 1325–1328. <https://doi.org/10.1001/archinte.155.12.1325>
- Pauletto, G., Soares, P. M., Baumhardt, T., Pereira, G. K. R., & Bier, C. A. S. (2024). Effect of radiotherapy and taper of root canal preparation on the biomechanical behavior of mesial roots of mandibular molars. *Journal of Endodontics*, 50(6), 827-834.
- Pernot, M., Luporsi, E., Hoffstetter, S., Peiffert, D., Aletti, P., Marchal, C., Kozminski, P., Noël, A., & Bey, P. (1997). Complications following definitive irradiation for cancers of the oral cavity and the oropharynx (in a series of 1134 patients). *International journal of radiation oncology, biology, physics*, 37(3), 577–585. [https://doi.org/10.1016/s0360-3016\(96\)00612-8](https://doi.org/10.1016/s0360-3016(96)00612-8)
- Pioch, T., Golfels, D., & Staehle, H. J. (1992). An experimental study of the stability of irradiated teeth in the region of the dentinoenamel junction. *Endodontics & Dental Traumatology*, 8(6), 241–244. <https://doi.org/10.1111/j.1600-9657.1992.tb00251.x>
- Raber-Durlacher, J. E., Epstein, J. B., Raber, J., van Dissel, J. T., van Winkelhoff, A. J., Guiot, H. F., & van der Velden, U. (2002). Periodontal infection in cancer patients treated with high-dose chemotherapy. *Supportive care in cancer : official journal of the Multinational Association of Supportive Care in Cancer*, 10(6), 466–473. <https://doi.org/10.1007/s00520-002-0346-3>
- Rettig, E.M., & D’Souza, G. (2015). Epidemiology of head and neck cancer, *Surgical Oncology Clinics*, 24(3), 379-396. (y.y.) 24(3), 379-396.
- Rosenthal, D. I., & Trotti, A. (2009). Strategies for managing radiation-induced mucositis in head and neck cancer. *Seminars in Radiation Oncology*, 19(1), 29–34. <https://doi.org/10.1016/j.semradonc.2008.09.006>
- Rubenstein, E. B., Peterson, D. E., Schubert, M., Keefe, D., McGuire, D., Epstein, J., Elting, L. S., Fox, P. C., Cooksley, C., Sonis, S. T. (2004). Mucositis Study Section of the Multinational Association for Supportive Care in Cancer, & International Society for Oral Oncology. Clinical practice guidelines for the prevention and treatment of cancer therapy-induced oral and gastrointestinal mucositis. *Cancer*, 100(9 Suppl), 2026–2046. <https://doi.org/10.1002/cncr.20163>
- Russell, N. S., & Bartelink, H. (1999). Radiotherapy: the last 25 years. *Cancer treatment reviews*, 25(6), 365–376. <https://doi.org/10.1053/ctrv.1999.0141>.
- Santin, G. C., Palma-Dibb, R. G., Romano, F. L., de Oliveira, H. F., Nelson Filho, P., & de Queiroz, A. M. (2015). Physical and adhesive properties of dental enamel after radiotherapy and bonding of metal and ceramic brackets. *American Journal Of Orthodontics And Dentofacial Orthopedics : Official Publication of the American Association of Orthodontists, its Constituent Societies, and the American Board of Orthodontics*, 148(2), 283–292. <https://doi.org/10.1016/j.ajodo.2015.03.025>

- Saund, D., Kotecha, S., Rout, J., & Dietrich, T. (2010). Non-resolving periapical inflammation: a malignant deception. *International Endodontic Journal*, 43(1), 84–90. <https://doi.org/10.1111/j.1365-2591.2009.01644.x>
- Schubert MM, Epstein JB, Peterson DE. (1998). Oral complications of cancer therapy. *Pharmacology and Therapeutics for Dentistry* 4th ed. St Louis: Mosby-Year Book Inc; p. 644-55.
- Schweyen, R., Kuhnt, T., Wienke, A., Eckert, A., & Hey, J. (2017). The impact of oral rehabilitation on oral health-related quality of life in patients receiving radiotherapy for the treatment of head and neck cancer. *Clinical oral investigations*, 21(4), 1123–1130. <https://doi.org/10.1007/s00784-016-1874-4>
- Scully, C., Epstein, J., & Sonis, S. (2004). Oral mucositis: a challenging complication of radiotherapy, chemotherapy, and radiochemotherapy. Part 2: diagnosis and management of mucositis. *Head & Neck*, 26(1), 77–84. <https://doi.org/10.1002/hed.10326>
- Silva, A. R., Alves, F. A., Berger, S. B., Giannini, M., Goes, M. F., & Lopes, M. A. (2010). Radiation-related caries and early restoration failure in head and neck cancer patients. A polarized light microscopy and scanning electron microscopy study. *Supportive care in cancer : official journal of the Multinational Association of Supportive Care in Cancer*, 18(1), 83–87. <https://doi.org/10.1007/s00520-009-0633-3>
- Soares, C. J., Castro, C. G., Neiva, N. A., Soares, P. V., Santos-Filho, P. C. F., Naves, L. Z., & Pereira, P. N. R. (2010). Effect of gamma irradiation on ultimate tensile strength of enamel and dentin. *Journal of Dental Research*, 89(2), 159–164. https://doi.org/10.1177/0022034509351251/ASSET/IMAGES/LARGE/10.1177_0022034509351251-FIG3.JPG
- Soares, C. J., Roscoe, M. G., Castro, C. G., Santana, F. R., Raposo, L. H. A., Quagliatto, P. S., & Novais, V. R. (2011). Effect of gamma irradiation and restorative material on the biomechanical behaviour of root filled premolars. *International Endodontic Journal*, 44, 1047–1054. <https://doi.org/10.1111/j.1365-2591.2011.01920.x>
- Sonis, S. T., Eilers, J.P., & Epstein, J. B. (1998). Dutch Association of Oral and Maxillofacial Surgery. Published online, doi:10.1002/(SICI)1097-0142(19990515)85:10.
- Springer, I. N., Niehoff, P., Warnke, P. H., Böcek, G., Kovács, G., Suhr, M., Wiltfang, J., & Açil, Y. (2005). Radiation caries--radiogenic destruction of dental collagen. *Oral Oncology*, 41(7), 723–728. <https://doi.org/10.1016/j.oraloncology.2005.03.011>
- Sroussi, H. Y., Epstein, J. B., Bensadoun, R. J., Saunders, D. P., Lalla, R. V., Migliorati, C. A., Heavilin, N., & Zumsteg, Z. S. (2017). Common oral complications of head and neck cancer radiation therapy: mucositis, infections, saliva change, fibrosis, sensory dysfunctions, dental caries, periodontal disease, and osteoradionecrosis. *Cancer Medicine*, 6(12), 2918–2931. <https://doi.org/10.1002/cam4.1221>

- Starcke, E. N., & Shannon, I. L. (1977). How critical is the interval between extractions and irradiation in patients with head and neck malignancy?. *Oral surgery, oral medicine, and oral pathology*, 43(3), 333–337. [https://doi.org/10.1016/0030-4220\(77\)903](https://doi.org/10.1016/0030-4220(77)903).
- Stimson, S., Harrison, L., & Forastiere, A., (1997). Tumors of the nasal cavity and paranasal sinuses, larynx, oral cavity and oropharynx. In: De Vita V, Hellman S, Rsenberg S, editor: *Cancer: principles and practice of oncology*, 5th ed, Philadelphia: Lippincott-Raven, 1. 752.
- T.C. Sağlık Bakanlığı. (2016). Kanser İstatistikleri. Erişim <https://hsgm.saglik.gov.tr/tr/kanseristatistikleri/yillar/2016-yili-turkiye-kanser-i-statistikleri.html>. (y.y.).
- Trotti, A., Bellm, L. A., Epstein, J. B., Frame, D., Fuchs, H. J., Gwede, C. K., Komaroff, E., Nalysnyk, L., & Zilberberg, M. D. (2003). Mucositis incidence, severity and associated outcomes in patients with head and neck cancer receiving radiotherapy with or without chemotherapy: a systematic literature review. *Radiotherapy and Oncology: Journal of the European Society for Therapeutic Radiology and Oncology*, 66(3), 253–262. [https://doi.org/10.1016/s0167-8140\(02\)00404-8](https://doi.org/10.1016/s0167-8140(02)00404-8)
- Trotti A. (2000). Toxicity in head and neck cancer: a review of trends and issues. *International Journal of Radiation Oncology, Biology, Physics*, 47(1), 1–12. [https://doi.org/10.1016/s0360-3016\(99\)00558-1](https://doi.org/10.1016/s0360-3016(99)00558-1)
- Uzal C. (1995). Kanserde ışınlama teknikleri. Ankara, Öncü Yayıncılık. 301-311.
- Uzel, R. (1999). Radyasyon Onkolojisininin Dünyada ve Ülkemizde Gelişme Süresi ve Bugünkü Durumu. *Kanser Gündemi*.
- Visch, L. L., Scholtemeijer, M., Denissen, H. W., Kalk, W., & Levendag, P. C. (1994). Use of implants for prosthetic rehabilitation after cancer treatment: clinical experiences. *Journal of investigative surgery : the official journal of the Academy of Surgical Research*, 7(4), 291–303. <https://doi.org/10.3109/08941939409051147>
- Vissink, A., Jansma, J., Spijkervet, F. K. L., Burlage, F. R., & Coppes, R. P. (2003). Oral sequelae of head and neck radiotherapy. *Critical Reviews in Oral Biology and Medicine*, 14(3), 199–212. <https://doi.org/10.1177/154411130301400305>
- Walker, M. P., Wichman, B., Cheng, A. L., Coster, J., & Williams, K. B. (2011). Impact of Radiotherapy Dose on Dentition Breakdown in Head and Neck Cancer Patients. *Practical radiation oncology*, 1(3), 142–148. <https://doi.org/10.1016/j.prro.2011.03.003>.
- Weissheimer, T., Bruna Barcelos, S., Pradebon, M. C., de Figueiredo, J. A. P., Martins, M. D., & Marcus Vinicius Reis, S. (2022). Head and neck radiotherapy effects on the dental pulp vitality and response to sensitivity tests: A systematic review with meta-analysis. *International Endodontic Journal*, 55(6), 563–578. <https://doi.org/10.1111/IEJ.13726>

- Woo, S. B., Hellstein, J. W., & Kalmar, J. R. (2006). Narrative [corrected] review: bisphosphonates and osteonecrosis of the jaws. *Annals of internal medicine*, 144(10), 753–761. <https://doi.org/10.7326/0003-4819-144-10-200605160-00009>.
- Yaduka, P., Katakı, R., Roy, D., Das, L., & Goswami, S. (2021). Effects of radiation therapy on the dislocation resistance of root canal sealers applied to dentin and the sealer-dentin interface: a pilot study. *Restorative Dentistry & Endodontics*, 46(2). <https://doi.org/10.5395/RDE.2021.46.E22>
- Yamin, P. A., Pereira, R. D., Lopes, F. C., Queiroz, A. M., Oliveira, H. F., Saquy, P. C., & Sousa-Neto, M. D. (2018). Longevity of bond strength of resin cements to root dentine after radiation therapy. *International Endodontic Journal*, 51(11), 1301–1312. <https://doi.org/10.1111/iej.12945>
- Yazıcı G, Cengiz M, Yıldız F. (2011). Stereotaktik vücut radyaterapisi. *Hacettepe Tıp Dergisi*, 42: 74-81.
- Zeman, E. M., Schreiber, E.C., & Tepper, J.E., (2020). Basics of Radiation Therapy. *Abeloff's Clin Oncol.*, 431-460.e3. doi:10.1016/B978-0-323-47674-4.00027-X.

CHAPTER 6

VISUAL AIDS IN ENDODONTICS: THE ROLE OF MAGNIFICATION AND ILLUMINATION

*İdil ÖZDEN*¹

¹ Marmara University Faculty of Dentistry, Department of Endodontics, Istanbul, Turkey

Assist. Prof. İdil Özden, ORCID ID: 0000-0003-0838-4355

Marmara University Faculty of Dentistry, Department of Endodontics, Istanbul, Turkey

idil.akman94@gmail.com

Introduction

The rapid advancements in technology have facilitated significant progress in the field of dentistry, leading to the development of numerous new technologies and instruments that have made endodontic procedures more accessible. These innovations have allowed practitioners to perform procedures more easily that were previously considered difficult or could only be undertaken by individuals with specific skills. The aim of successful endodontic treatment is the complete mechanical and chemical cleansing of the entire root canal system, followed by filling it with a compatible filling material (Vertucci, 1984). In this process, establishing an ideal access angle emerges as one of the most crucial steps for a successful endodontic procedure. However, the failure to detect all canals within the root canal system and to treat them appropriately is one of the primary reasons leading to treatment failure and the persistence of disease (Weine, 1969; Sjögren, 1990; Wolcott, 2002; Dugas, 2003).

In recent years, particularly the introduction of magnification and illumination tools in the field of endodontics has provided significant advantages. The widespread use of these devices has enabled practitioners to obtain more detailed and precise views, making it possible to visualize and examine even the most apical parts of the root canal system. Additionally, the use of microscopic surgical instruments has introduced technical innovations in root canal preparation processes and has enhanced the quality of clinical applications (Uzun et al., 2012; Sengezer et al., 2017).

Among the magnification devices commonly used in endodontics are loupes, surgical microscopes (Rubinstein, 1999; Castellucci, 2003), and more recently, endoscopes (Von Arx, 2002; Bahcall, 2003). Working with such devices has become a widely accepted practice in both conventional and surgical endodontics. It is stated that magnification and illumination devices increase accuracy in endodontic procedures and enhance diagnostic capacity by providing better visualization of the treatment area. For instance, these devices facilitate the detection and treatment of isthmuses, accessory canals, or root micro-cracks (Rampado, 2004; Von Arx, 2005). Additionally, the use of loupes and microscopes improves clinician ergonomics, contributing to the prevention of repetitive stress injuries associated with poor posture (Behle, 2001; Perrin, 2002). These technical advantages offered by magnification devices can also provide benefits for patients, such as higher treatment success rates, shorter treatment times, and lower overall costs.

Magnification in Endodontics

The use of magnification devices in dentistry is becoming increasingly widespread with the aim of enhancing treatment quality. Particularly in the field of endodontics, the application of microscopic surgical principles has accelerated efforts to develop new techniques in root canal therapy and to improve the visualization of the surgical field. It is recommended that well-focused illumination and magnification devices become standard in endodontic treatments (Kim, 2004; Cohen, 2006). Numerous studies in the literature have reported that magnification devices offer clinicians various technical advantages and enable the detection of microscopic anatomical structures invisible to the naked eye. This suggests that the quality of treatment can be significantly improved (Gorduysus, 2001; Baldassari-Cruz, 2002; Schwartz, 2002). These devices have the potential to enhance clinical outcomes by allowing for more precise and detailed management of the root canal system.

Various studies have reported that the technical advantages provided by magnification devices allow clinicians to identify microscopic structures that cannot be detected with the naked eye, which can significantly improve treatment quality (Slaton, 2003; Zaugg, 2004). Clinical outcomes may not always be directly affected by the type of magnification device used; however, the technical advantages offered by these devices can provide significant benefits in specific clinical situations, increasing confidence in patient care. Additionally, magnification devices facilitate the detection of prominent anatomical structures such as dentin cracks or isthmuses, thereby improving the treatment process.

Optical Systems: Galilean and Prismatic

Two main optical systems used in operating microscopes and loupes are the prismatic systems and the Galilean systems. Galilean systems are the most commonly used. However, because this system is limited by spherical aberrations, the magnification capacity generally remains at levels of $\times 3.5$ or lower. As the magnification rate increases, distortions in image quality occur. Additionally, one of the disadvantages of Galilean lens systems is that they create a light ring effect around the visual field, which can be distracting. Nevertheless, Galilean systems are preferred due to their lightweight nature and cost-effectiveness (James et al., 2010).

On the other hand, prismatic systems offer the highest optical quality. In prismatic loupes, light is directed through a series of internal reflections via prisms, providing better magnification quality. They also offer a wider field of view and greater depth of field. The disadvantages of this system are that it is heavier, has a longer lens structure, and is more expensive.

Prismatic loupes can be used at different magnification levels and offer superior optical performance (James et al., 2010).

Both types of lenses can be mounted onto eyeglass frames or integrated into eyeglass lenses. Adjustable loupes mounted on the frame allow the clinician to adjust the viewing angle and interpupillary distance and are less expensive. However, disadvantages of this design include being heavier and providing a narrower field of view. Loupes fixed onto eyeglass lenses are adjusted and fixed according to the operator's working distance and interpupillary distance. Such loupes offer a wider field of view. Although they are lighter, they are more expensive and generally cannot be removed during treatment to glance around or converse with the patient. Additionally, small adjustment errors can lead to eye fatigue during prolonged use (more than 30 minutes) (Carr et al., 2002).

Galilean and prismatic systems are also employed in operating microscopes. Both systems provide good magnification while offering a large depth of field and a focal length ranging between 30–45 cm. This reduces eye, head, and neck fatigue and allows for customization according to personal working distance and interpupillary distance. However, a disadvantage of loupes is that the maximum practical magnification is generally limited to only $\times 4.5$. While models offering higher magnification are available, they are typically heavy and bulky, with narrow fields of view. Some manufacturers have achieved magnification levels ranging from $\times 2.5$ to $\times 6$ using computer-assisted technologies. However, such loupes require a restricted physical posture, which can lead to head, neck, and back pain during prolonged use (Castellucci et al., 2003).

Operating microscopes, on the other hand, feature adjustable magnification levels controlled by manual or motorized foot pedals. Clinicians should perform most procedures at low or medium magnification levels and use maximum magnification only during inspection phases of the procedure, because as magnification increases, the depth and width of the operative field decrease.

Illumination in Endodontics

During root canal treatment, clinicians encounter inadequate illumination not only due to the low light levels within the oral cavity but also within the pulp chamber and root canals. This situation necessitates the use of powerful light sources added to dental units. Light intensity is determined by the inverse square law; that is, when the distance between the light source and the object is doubled, the amount of light reaching the object decreases by a factor of four. Within the mouth, especially when working in root canals, the required light is often insufficient due to the distance

from the light source. Additionally, as the amount of light reaching the object increases, the eye's ability to discern finer details—its resolution—also improves.

In cases where illumination is inadequate, lamps mounted on loupes can be utilized. These lamps operate using fiber optic cables or LED light sources and allow the light to be directed in tandem with the clinician's head movements. Devices that use fiber optic cables produce minimal heat; however, the proximity of the cable connection to the clinician can restrict freedom of movement. LED light sources, on the other hand, may offer greater freedom of movement. Headlamps can provide light levels up to four times that of traditional dental lights. Moreover, an additional advantage of these lamps is that the light is directed in the same direction as the clinician's head movements (Carr et al., 2002).

Operating microscopes, which are among the most effective devices for illumination, provide strong lighting down to the deepest parts of the root canal. The use of light intensities up to 30,000 lux in the operative field is considered safe, as it reduces glare effects (James et al., 2010). However, much brighter LED lights are also available; these lights may cause increased glare by reflecting off tooth surfaces and may not be safe for prolonged use (Shanelec et al., 1992). Halogen or xenon light sources used in microscopes can be equipped with various filters to enhance visual comfort during procedures. Filters can be employed to prevent blood reflection (green filter) or to prevent the premature polymerization of resin materials (yellow-orange filter).

Recommendations for the Use of Magnification and Illumination

1. To enhance precision and detailed visualization in endodontic procedures, the use of magnification devices (loupes or operating microscopes) should be encouraged. Considering the advantages of Galilean and prismatic systems, devices should be selected that align with the clinician's working style and needs. Prismatic systems, which offer higher magnification and a wider field of view, may be particularly preferred for clearer visualization of the complex anatomy of the root canal system.
2. During endodontic procedures, especially to illuminate deep root canals, operating microscopes providing coaxial illumination should be utilized. These devices deliver direct light without any angle or shadow, allowing for clear visualization of the treatment area and enabling more precise interventions.

3. Attention should be paid to the ergonomic posture of the clinician when using magnification devices. Properly adjusted loupes or microscopes can reduce head, neck, and back fatigue, thereby preventing long-term occupational injuries. Additionally, to prevent eye strain, it is important to ensure that the devices are correctly calibrated and that the interpupillary distance is properly set.

REFERENCES

- Bahcall, J. K., Barss, J. (2003). Orascope visualization technique for conventional and surgical endodontics. *International Endodontic Journal*, 36(6), 441-447. [MEDLINE: 12870474]
- Baldassari-Cruz, L. A., Lilly, J. P., Rivera, E. M. (2002). The influence of dental operating microscope in locating the mesiolingual canal orifice. *Oral Surgery, Oral Medicine, Oral Pathology, Oral Radiology and Endodontology*, 93(2), 190-194.
- Behle, C. (2001). Photography and the operating microscope in dentistry. *Journal of the Californian Dental Association*, 29(10), 765-771. [MEDLINE: 11799672]
- Carr, G. B., Murgel, C. A. (2010). The use of the operating microscope in endodontics. *Dent Clin North Am*, 54, 191-214.
- Castellucci, A. (2003). Magnification in endodontics: the use of the operating microscope. *Pract Proced Aesthet Dent*, 15, 377-384. [MEDLINE: 12901065]
- Dugas, N. N., Lawrence, H. P., Teplitsky, P. E., Pharoah, M. J., Friedman, S. (2003). Periapical health and treatment quality assessment of root-filled teeth in two Canadian populations. *International Endodontic Journal*, 36(3), 181-192. [MEDLINE: 12657144]
- Germano, F., Melone, P., Testi, D., Arcuri, L., Marmioli, L., Petrone, A., & Arcuri, C. (2015). Oral complications of head and neck radiotherapy: prevalence and management. *Minerva Stomatol*, 64(4), 189-202.
- Görduysus, M. O., Görduysus, M., Friedman, S. (2001). Operating microscope improves negotiation of second mesiobuccal canals in maxillary molars. *Journal of Endodontics*, 27(11), 683-686.
- James, T., Gilmour, A. S. (2010). Magnifying loupes in modern dental practice: an update. *Dent Update*, 37, 633-636.
- Perrin, P., Jacky, D., Hotz, P. (2002). The operating microscope in dental practice: minimally invasive restorations. *Schweizer Monatsschri. für Zahnmedizin*, 112(7), 722-732. [MEDLINE: 12185726]
- Rampado, M. E., Tjaderhane, L., Friedman, S., Hamstra, S. J. (2004). The benefit of operating microscope for access cavity preparation by undergraduate students. *Journal of Endodontics*, 30(12), 863-867. [MEDLINE: 15564865]
- Rubinstein, R. A., Kim, S. (1999). Short-term observation of the results of endodontic surgery with the use of a surgical operation microscope and Super-EBA as root-end filling material. *Journal of Endodontics*, 25, 43-48.
- Schwartz, T., Baethge, C., Stecher, T., Geurtsen, W. (2002). Identification of second canals in the mesiobuccal root of maxillary first and second molars using magnifying loupes or an operating microscope. *Australian Endodontic Journal*, 28(2), 57-60. [MEDLINE: 12360670]

- Sengezer, Ö., & Uzun, Ö. (2017). Endodonti kliniğinde kullanılan geliştirilmiş görüş araçları: dental mikroskoplar. *Türkiye Klinikleri Endodontics-Special Topics*, 3(2), 140-148.
- Shanelec, D. (1992). Optical principles of loupes. *Calif Dent Assoc*, 20, 25-32.
- Sjogren, U., Hagglund, B., Sundqvist, G., Wing, K. (1990). Factors affecting the long-term results of endodontic treatment. *Journal of Endodontics*, 16(10), 498-504. [MEDLINE: 2084204]
- Slaton, C. C., Loushine, R. J., Weller, R. N., Parker, M. H., Kimbrough, W. F., Pashley, D. H. (2003). Identification of resected root-end dentinal cracks: a comparative study of visual magnification. *Journal of Endodontics*, 29(8), 519-522. [MEDLINE: 12929699]
- Uzun, Ö., & Yalpi, F. (2011). Endodontide büyütme ve aydınlatma. *Gazi Üniversitesi Diş Hekimliği Fakültesi Dergisi*, 29(1), 51-61.
- Vertucci, F. J. (1984). Root canal anatomy of the human permanent teeth. *Oral Surgery, Oral Medicine, Oral Pathology*, 58(5), 589-599.
- Von Arx, T., Hunenbart, S., Buser, D. (2002). Endoscope- and video-assisted endodontic surgery. *Quintessence International*, 33(4), 255-259. [MEDLINE: 11989374]
- Von Arx, T. (2005). Frequency and type of canal isthmuses in first molars detected by endoscopic inspection during periradicular surgery. *International Endodontic Journal*, 38(3), 160-168. [MEDLINE: 15743419]
- Weine, F. S., Healey, H. J., Gerstein, H., Evanson, L. (1969). Canal configuration in the mesiobuccal root of the maxillary first molar and its endodontic significance. *Oral Surgery, Oral Medicine, Oral Pathology*, 28(3), 419-425. [MEDLINE: 5257186]
- Wolcott, J., Ishley, D., Kennedy, W., Johnson, S., Minnich, S. (2002). Clinical investigation of second mesiobuccal canals in endodontically treated and retreated maxillary molars. *Journal of Endodontics*, 28(6), 477-479. [MEDLINE: 12067135]
- Zaugg, B., Stassinakis, A., Hotz, P. (2004). Influence of magnification tools on the recognition of simulated preparation and filling errors. *Schweizer Monatsschri. für Zahnmedizin*, 114(9), 890-896.